



Continuum Health Partners, Inc.

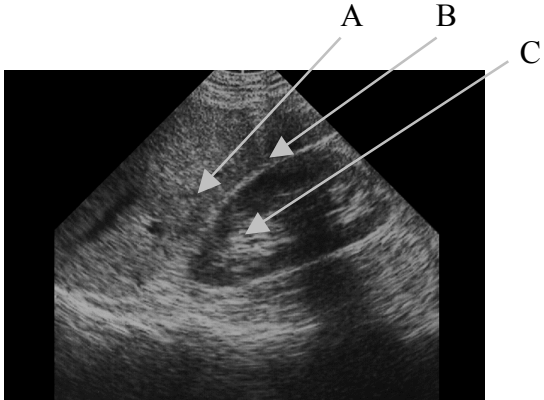
## SLRHC Credentialing Examination Abdominal FAST

Circle the single best answer:

- 1) What does FAST stand for?
  - A) Fast application of sonography in trauma
  - B) Fast abdominal sonography in trauma
  - C) Focused abdominal sonography in trauma
  - D) Focused application of sonography in trauma
  - E) Focused assessment of sonography in trauma
  
- 2) All of the following are true of the FAST examination in the evaluation of blunt abdominal trauma (BAT) EXCEPT:
  - A) Reproducible
  - B) Rapid
  - C) Non-invasive
  - D) Safe in pregnancy
  - E) Easy to distinguish blood from ascites
  
- 3) All of the following are true of the FAST examination in the evaluation of BAT EXCEPT:
  - A) Operator dependent
  - B) Not organ specific
  - C) Difficult in obese patients
  - D) Able to evaluate the retroperitoneum
  - E) Difficult to distinguish blood from ascites
  
- 4) The most dependent area of the peritoneal cavity in the supine patient is:
  - A) Hepato-renal/Morrison's pouch
  - B) Spleno-renal recess
  - C) Right paracolic gutter
  - D) Left paracolic gutter
  - E) Rectovesical/Douglas pouch
  
- 5) The only absolute contraindication to performing the FAST examination is:
  - A) Pregnancy
  - B) Hemodynamically unstable patient
  - C) Clear indication for operative management
  - D) Intoxication
  - E) Penetrating abdominal trauma

- 6) All of the following are mimics of a positive FAST examination EXCEPT:
- A) Pericardial fat
  - B) Perinephric fat
  - C) Ascites
  - D) Full bladder
  - E) Physiologic free fluid in Douglas' pouch
- 7) The FAST examination may detect injury to all of the following organs except:
- A) Liver
  - B) Kidney
  - C) Spleen
  - D) Bladder
  - E) Pancreas
- 8) Each of the following is a standard view for the FAST examination EXCEPT:
- A) Hepato-renal recess
  - B) Transverse proximal aorta
  - C) Spleno-renal recess
  - D) Recto-vesical
  - E) Subxiphoid
- 9) A patient presents with BAT and stable vital signs. FAST exam shows no fluid. 30 minutes later, the patients BP drops and HR increases. At this time, the quickest and easiest test to perform would be:
- A) DPL
  - B) CT scan
  - C) Repeat FAST
  - D) Exploratory laparotomy
  - E) Upright chest x-ray
- 10) The optimal patient position to maximize visualization of free fluid in Morrison's pouch:
- A) Left lateral decubitus
  - B) Right lateral decubitus
  - C) Bent knees
  - D) Trendelenburg
  - E) Reverse trendelenburg

Identify the following scan of the RUQ area:



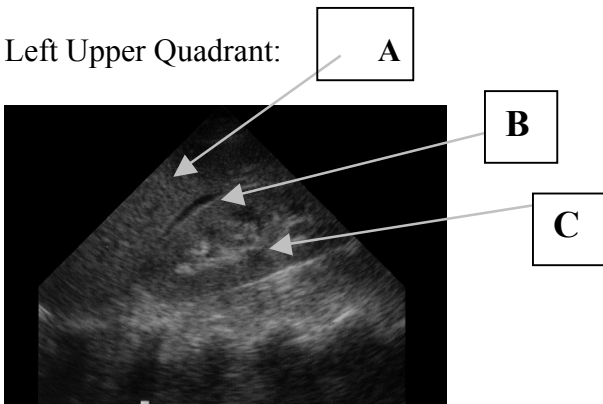
A \_\_\_\_\_

B \_\_\_\_\_

C \_\_\_\_\_

D True/False: This is a positive FAST exam

Left Upper Quadrant:



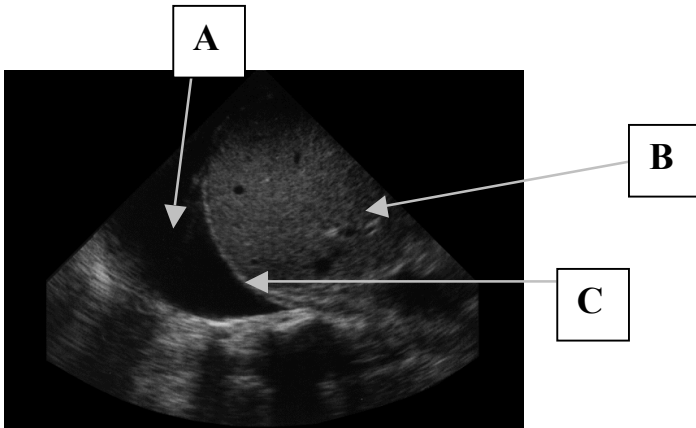
A \_\_\_\_\_

B \_\_\_\_\_

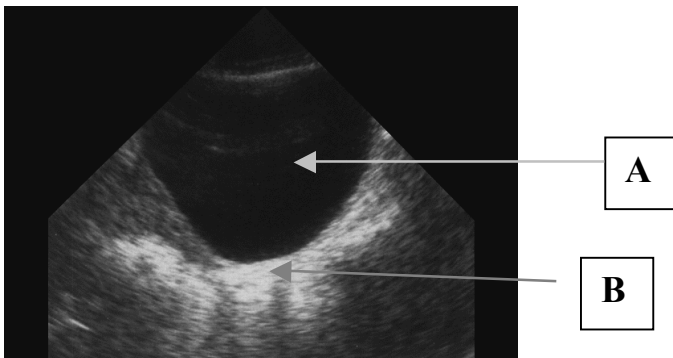
C \_\_\_\_\_

D. True/False: This is a positive FAST exam

Left Upper Quadrant area:



- A \_\_\_\_\_
- B \_\_\_\_\_
- C \_\_\_\_\_
- D. Diagnosis: \_\_\_\_\_



- A \_\_\_\_\_
- B \_\_\_\_\_
- C. True/False This is a positive FAST exam