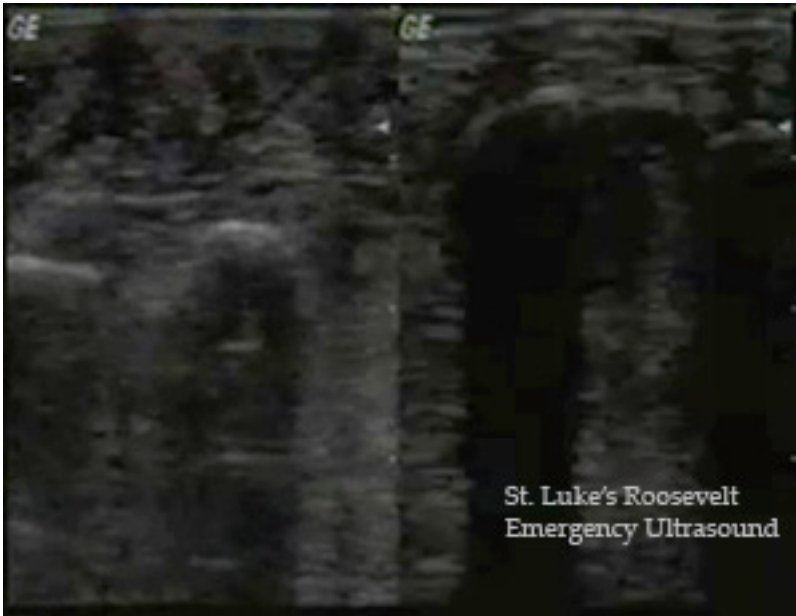


Emergency Ultrasound Credentialing Exam- Abscess/Cellulitis

Circle the best answer.

- 1. The best probe for soft tissue evaluation is a HIGH/LOW (circle) frequency.
- 2. True/False A comparison view demonstrating a normal unaffected side should always be included in the evaluation of abscess/cellulitis
- 3. True/False Cellulitis is marked by a cobblestone pattern.



The above image demonstrates foot cellulitis with a comparison view. Mark the cellulitic side A and the normal side B

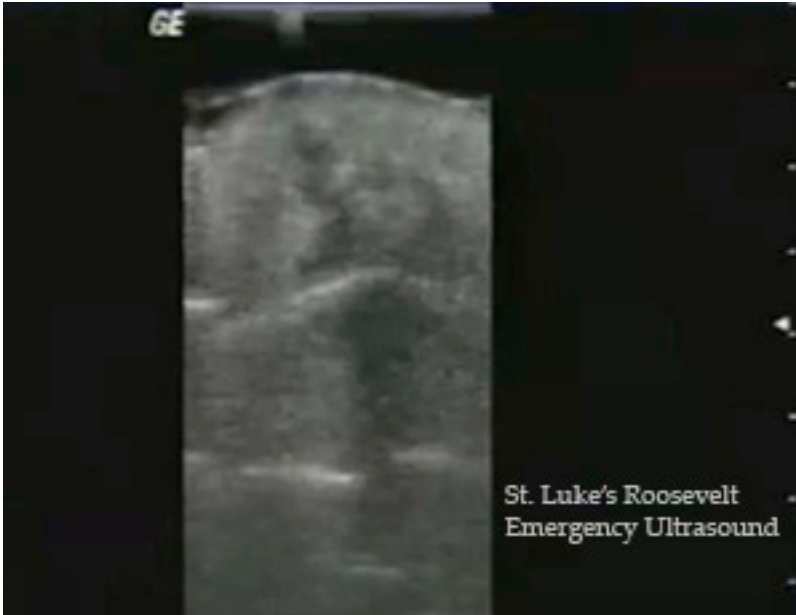Describe 3 reasons for your answer:

---

---

---

---

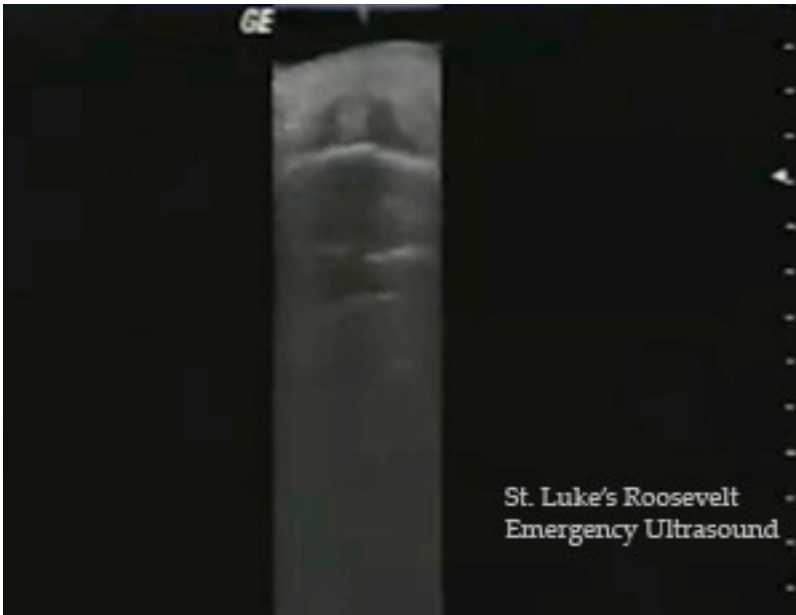

Circle the appropriate answer CELLULITIS/ABSCESS  
Describe 3 reasons for your answer:

---

---

---



Circle the appropriate answer CELLULITIS/ABSCESS  
Describe 3 reasons for your answer:

---

---