

# Emergency Clinician–Performed Compression Ultrasonography for Deep Venous Thrombosis of the Lower Extremity

**Jeffrey A. Kline, MD**

**Patrick M. O'Malley, MD**

**Vivek S. Tayal, MD**

**Gregory R. Snead, MD**

**Alice M. Mitchell, MS, MD**

From the Department of Emergency Medicine, Carolinas Medical Center, Charlotte, NC (Kline, Tayal, Mitchell); Lexington Medical Center, Columbia, SC (O'Malley); and the Department of Emergency Medicine, Wishard Hospital, Indianapolis, IN (Snead).

**Study objective:** Emergency clinician–performed ultrasonography holds promise as a rapid and accurate method to diagnose and exclude deep venous thrombosis. However, the diagnostic accuracy of emergency clinician–performed ultrasonography performed by a heterogeneous group of clinicians remains undefined.

**Methods:** Prospective, single-center study conducted at an urban, academic emergency department (ED). Clinician participants included ED faculty, supervised residents, and midlevel providers who completed a training course for above-calf, 3-point-compression, venous ultrasonography. Patient participants had suspected leg deep venous thrombosis and greater than or equal to 1 predefined sign or symptom. Before any imaging, clinicians classified patients as low (<15%), moderate (15% to 40%), or high (>40%) pretest probability of deep venous thrombosis, followed by emergency clinician–performed ultrasonography. A whole-leg reference venous ultrasonography was then performed and interpreted separately in the radiology department. Patients were followed for 30 days. The criterion standard for deep venous thrombosis(+), required thrombosis of any leg vein on a reference ultrasonograph and clinical plan to treat.

**Results:** We enrolled 183 patients, and 27 (15%) had deep venous thrombosis(+). The sensitivity and specificity emergency clinician–performed ultrasonography was 70% (95% confidence interval [CI] 60% to 80%) and 89% (95% CI 83% to 94%), respectively, with overall diagnostic accuracy of 85% (95% CI 79% to 90%). The posterior probability of deep venous thrombosis(+) among the 88 low-risk patients with a negative emergency clinician–performed ultrasonographic result was 1 of 88, or 1.1% (95% CI 0% to 6%), and the posterior probability of deep venous thrombosis(+) among 14 high-risk patients with a positive emergency clinician–performed ultrasonographic result was 11 of 14, or 79% (95% CI 49% to 95%).

**Conclusion:** The overall diagnostic accuracy of single-visit emergency clinician–performed ultrasonography performed by a heterogeneous group of ED clinicians is intermediate but may be improved by pretest probability assessment. [Ann Emerg Med. 2008;xx:xxx.]

0196-0644/\$-see front matter

Copyright © 2008 by the American College of Emergency Physicians.

doi:10.1016/j.annemergmed.2008.05.023

## INTRODUCTION

Failure to promptly diagnose and properly treat deep venous thrombosis can directly worsen outcomes for patients by increasing their risk of subsequent pulmonary embolism and the postphlebotic syndrome.<sup>1,2</sup> However, the erroneous diagnosis of deep venous thrombosis can lead to unnecessary treatment with anticoagulation and the attendant risk of hemorrhage. To help exclude the diagnosis of deep venous

thrombosis, some emergency department (ED) clinicians use the D-dimer assay; however, D-dimer testing can allow exclusion of deep venous thrombosis in fewer than half of patients with suspected deep venous thrombosis and cannot confirm the diagnosis of deep venous thrombosis.<sup>3</sup> Venous ultrasonography remains the main modality used to exclude and diagnose deep venous thrombosis in the ED setting. However, consultative venous ultrasonography requires

**Editor's Capsule Summary***What is already known on this topic*

Research has suggested that emergency physician–performed bedside ultrasonography to rule out deep venous thrombosis is a convenient, efficient, and accurate alternative to such studies in the radiology department.

*What question this study addressed*

How accurate is a heterogeneous group of emergency clinicians (attending physicians, residents, and midlevel providers) in performing venous ultrasonography for deep venous thrombosis compared with confirmatory ultrasonographic studies performed by the department of radiology?

*What this study adds to our knowledge*

In 183 patients, 27 of whom had radiologist–confirmed deep venous thrombosis, the emergency department examination was 70% sensitive and 89% specific.

*How this might change clinical practice*

The diagnostic accuracy found in this study is less than that previously reported, raising concern about more widespread application of this practice. However, the existence of heterogeneity among operators and improvement with repetition suggest that test performance may be dependent on operator interest and experience.

significant time, patient transport, availability of an appropriately credentialed medical sonographer, and a board-certified radiologist.

Most emergency medicine residencies in the United States include training in focused, bedside ultrasonography. In a recent systematic review, Burnside et al<sup>4</sup> found excellent diagnostic accuracy for emergency clinician–performed ultrasonography of the lower extremities. This evidence may cause thought leaders in the field of emergency ultrasonography to consider the addition of venous ultrasonography as part of standard ultrasonographic training. However, the bulk of the previous studies were performed by emergency clinicians with special interest and training in emergency ultrasonography. We are unaware of any study demonstrating the diagnostic accuracy of emergency clinician–performed ultrasonography when performed by a large, heterogeneous group of emergency clinicians, all of whom routinely perform other ultrasonographic examinations in the ED but have variable levels of ultrasonographic expertise and experience. We hypothesized an overall diagnostic accuracy not worse than 90%, according to the results of a systemic review of previous reports of emergency clinician–performed ultrasonography.<sup>4</sup>

**MATERIALS AND METHODS****Theoretical Model of the Problem**

A systematic review of emergency clinician–performed ultrasonography found 6 studies that were conducted by a small or unstated number of clinicians on a patient population for which the clinical characteristics were not well described; follow-up was reported in only 2 studies, and the follow-up methodology was not described. We planned a prospective study to assess the diagnostic accuracy of emergency clinician–performed ultrasonography performed by a heterogeneous group of ED clinicians with variable levels of ultrasonographic experience.

This study was approved by the institutional review board at Carolinas Medical Center. Written, informed consent was obtained from clinician and patient participants. A study author (J.A.K.) obtained informed consent from all clinician–participants. Informed consent from patients was obtained by a study author, a research coordinator, or clinician participants who had given consent. All persons obtaining informed consent had completed an approved Good Clinical Practice training program within the previous year. The institutional review board mandated a requirement that this study be monitored by a board-certified radiologist with current hospital credentialing for lower extremity venous ultrasonography. The protocol specified that the study be stopped if the following criteria for immediate clinical worsening were met after 30 patients were enrolled: more than 10% of patients had clinical worsening after emergency clinician–performed ultrasonography but before the consultative ultrasonography, in which clinical worsening was defined as a greater than 25% decrease in systolic blood pressure, or respiratory distress requiring medical intervention, and the patient was diagnosed with pulmonary embolism within 24 hours.

**Setting**

This study was performed at Carolinas Medical Center, a metropolitan teaching hospital with an emergency medicine residency and ED annual patient census of approximately 110,000. The emergency medicine residency has an established training program in focused, bedside ultrasonography. The authors have previously published in the area of goal-directed emergency ultrasonography.<sup>5,6</sup>

**Selection of Participants**

Emergency clinicians performing ultrasonography included emergency medicine attending physicians, fellows and supervised residents, and midlevel ED providers. We required all participating clinicians to have existing credentials at our hospital to perform focused first-trimester pelvic ultrasonography and focused abdominal sonographic examination for trauma. No clinician–participant was a registered diagnostic medical sonographer, and no participant had hospital credentials to perform venous ultrasonography.

Patient participants were self-referred ED patients. All patients were enrolled after they had undergone a medical

history and physical examination obtained or supervised by a board-certified emergency physician. Inclusion criteria required that the clinical team place an order for a consultative ultrasonographic examination of one or both lower extremities to rule out deep venous thrombosis and that the clinical team document one or more of the following conditions: (1) nontraumatic, unexplained leg discomfort within the previous week; (2) patient-reported unilateral leg swelling within the previous week; (3) leg asymmetry, unilateral leg edema, discoloration, tenderness, or swelling observed by the evaluating physician; or (4) suspected pulmonary embolism.

We excluded patients with any of the following: (1) consultative lower extremity ultrasonography performed in the radiology department within the previous 48 hours; (2) consultative ultrasonography ordered to examine the arm or neck veins and not the leg veins; (3) the presence of indwelling femoral vascular catheter or dialysis vascular shunts in the symptomatic leg; (4) a history of chronic deep venous thrombosis; (5) an above-knee amputation in the symptomatic leg; (6) the inability to access all 3 landmarks for 3-point ultrasonography because of the presence of a cast, external fixation apparatus, or other obstacle; or (7) conditions precluding telephone follow-up such as homelessness or incarceration. We planned in advance to exclude patients if the reference ultrasonography was not performed within 12 hours of enrollment.

All clinician participants completed a structured training course, completed Good Clinical Practice training (45 Code of Federal Regulations 46 and 21 Code of Federal Regulations 50), and were authorized by the institution to obtain informed consent for research studies. Briefly, the training course consisted of a 1-hour didactic lecture of the nomenclature and anatomy of the lower extremity venous system, the related functions of the ultrasonographic probe and machine, the technique for 3-point compression ultrasonography of the lower extremity venous system, the required criteria for negative emergency clinician-performed ultrasonographic findings, and instruction on how to complete the study data form. A syllabus of the didactic portion of this training course is available by contacting the corresponding author. Each clinician also completed 2 hours of practical examination, including a minimum of 5 proctored lower extremity venous ultrasonographic examinations on healthy volunteer models.

Clinicians recorded patient study data on a paper form immediately after informed consent. Residents and midlevel providers could be identified as the primary sonographer, but all such ultrasonographic procedures were supervised by attending physicians who had undergone the emergency clinician-performed ultrasonography training course. Before emergency clinician-performed ultrasonography, the evaluating ED clinician classified patients as low (<15%), moderate (15% to 40%), or high (>40%) pretest probability of deep venous thrombosis, according to the clinician's implicit interpretation of evidence and observations available when they populated the

data collection form. We have previously found this "gestalt" approach to produce results similar to those of scoring systems in pulmonary embolism.<sup>7</sup> The emergency clinician-performed ultrasonography was completed before the reference ultrasonographic examination.

The following steps summarize the image acquisition protocol for emergency clinician-performed ultrasonography.

1. Ultrasonographic examinations were performed on one of 2 machines (Ultrasonix CEP; Ultrasonix Corp, Vancouver, British Columbia, Canada) available continuously within the ED and were equipped with 14.5-MHz linear-format broadband probes.
2. The target veins at 3 sites were distinguished from the adjacent arteries and other structures by observation of the larger size relative to the artery and observation of respiratory collapse. As the discretion of the clinician, color Doppler could be used to help identify vein from artery.
3. Compressibility or coaptation of target veins was evaluated in the transverse view (marker to the right side of the patient). Care was taken to visualize complete anterior-to-posterior obliteration of the intravascular space. Adequate pressure for compression was defined as that necessary to efface the adjacent artery. Noncompressibility was deemed present when the artery flattened and the vein did not.
4. The patient was placed in reverse Trendelenburg position
5. The leg was placed in external rotation, with the knee slightly flexed.
6. The examiner identified the common femoral vein in transverse view at the level of the inguinal crease and assessed for compressibility.
7. The common femoral vein was then examined in its sagittal orientation (probe marker towards the patient's head). The common femoral vein was followed distally until it was observed to branch into the superficial and deep femoral veins. The common femoral was then assessed for compressibility in the transverse view.
8. The superficial femoral vein was followed under visual observation with the probe oriented sagittally and the marker toward the patient's head, until the probe was immediately superior to the adductor canal. The superficial femoral vein was then examined for compressibility in the transverse view.
9. The popliteal vein was examined with any of the following approaches at the discretion of the clinician performing the examination: (1) the patient in the supine position with the knee slightly flexed and externally rotated, (2) the patient in the decubitus position or (3) with the patient in the prone position, or (4) the patient seated on the examination table, with the leg in a dependent position off the table. The transducer was placed in the popliteal fossa in a transverse orientation (marker directed to the right side of the patient). The popliteal vein was identified as superficial and lateral to the popliteal artery, with color flow confirmation. Once identified, the popliteal vein is assessed for compressibility.

The emergency clinician–performed ultrasonographic results had to be interpreted as (a) normal compressibility, (b) noncompressible, or (c) not visualized (indeterminate) for each of the 3 veins on each leg examined: the common femoral vein, the superficial femoral vein, and the popliteal vein. The emergency clinician–performed ultrasonography was categorized as deep venous thrombosis(–) with interpretation (a) in all 3 vessels, and the emergency clinician–performed ultrasonography was categorized as deep venous thrombosis(+) with interpretation (b) or (c) in 1 or more vessel. Clinicians also reported the subjective level of difficulty in performing the study on a 0 to 10 scale (0=no difficulty and 10=impossible to perform).

All patient participants underwent a consultative radiology ultrasonographic examination of the same (or both) lower extremity performed in the radiology department on a separate floor within the same hospital within 12 hours of enrollment. Venous ultrasonographic images were performed and recorded by a registered diagnostic medical ultrasonographic technician certified in venous ultrasonography, using a standard institutional acquisition protocol that includes examination of the superficial and deep femoral veins, the popliteal veins and the saphenous vein, and the posterior tibial and peroneal veins. All consultative ultrasonographic examinations were interpreted in real time by a board-certified radiologist who was not made aware that the patient was enrolled in a study of emergency clinician–performed ultrasonography; neither the ultrasonographic technician nor radiologists had access to any research data. The radiologist interpretation of the consultative venous ultrasonography was used in the reference standard.

We recorded 2 telephone numbers and preferred times given by the patient for the follow-up telephone call. Starting 30 days after enrollment, we dialed both numbers on greater than or equal to 10 occasions at different times on separate days within a 2-week interval to contact the patient. On contact, we used a written script and data form to record answers to questions about the diagnosis and treatment of deep venous thrombosis since enrollment. We also performed a structured medical record review on all patients<sup>8</sup> and recorded the results of any consultative lower extremity ultrasonography or contrast venography examinations performed within 30 days and any clinical plan to treat for deep venous thrombosis, including systemic anticoagulation or vena caval filter insertion.

The reference standard for deep venous thrombosis(+) or deep venous thrombosis(–) was then established with an adjudication process requiring independent agreement of 2 authors who were blinded to both the emergency clinician–performed ultrasonographic images and emergency clinician–performed ultrasonographic interpretations using previously published methods.<sup>8</sup> The reference standard for deep venous thrombosis(+) required 2 adjudicators to agree that 2 endpoints occurred within 30 days: (1) any consultative lower extremity venous ultrasonography (or contrast venography) interpreted by a radiologist as positive for thrombosis in any vein in either

lower extremity, and (2) written evidence in the medical record indicating a clinical plan for treatment with greater than 89 days' systemic anticoagulation or a vena caval filter, or an autopsy report positive for pulmonary embolism or deep venous thrombosis.

According to previous work, we estimated a prevalence of deep venous thrombosis of 10%. Sample size of  $N=180$  was predicated with the method described by Arkin and Wachtel<sup>9</sup> to narrow confidence intervals (CIs) around the diagnostic accuracy of 0.90 to within  $\pm 10\%$ .

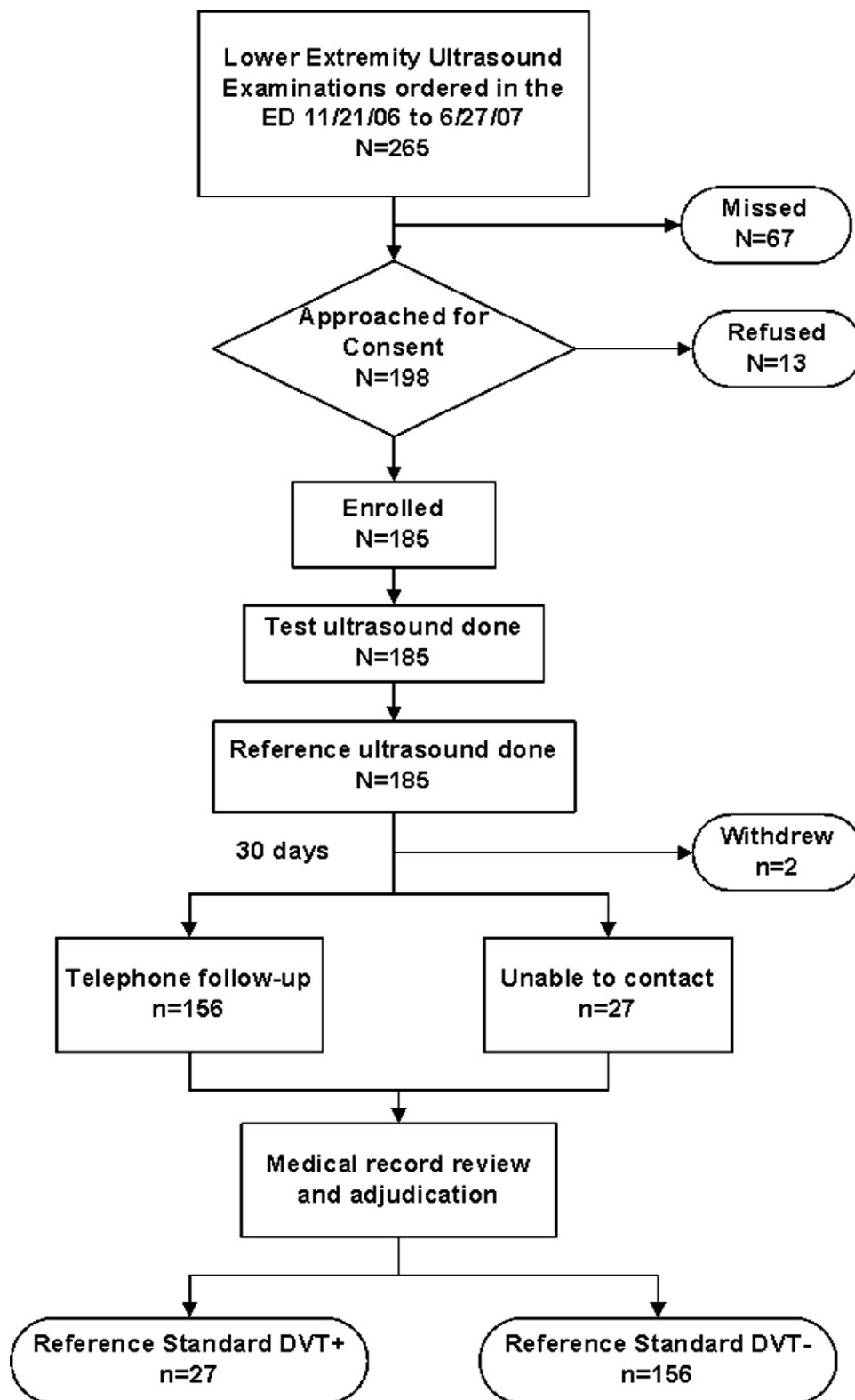
### Primary Data Analysis

The primary analysis was from diagnostic contingency tables. We computed sensitivity, specificity, and likelihood ratios, with associated 95% CIs. Analyses were done in StatsDirect (Cheshire, UK; version 2.4.4). The test ultrasonography was deep venous thrombosis(+) or deep venous thrombosis(–), using the definitions in the study protocol. The primary reference standard for deep venous thrombosis(+) required a reference ultrasonographic examination, performed at any time within 30 days of enrollment, positive for thrombosis in a femoral, popliteal, saphenous, or calf vein, followed by the clinical decision to treat with either a new vena caval filter or systemic anticoagulation for 90 days or longer. We then stratified diagnostic results according to the clinician's unstructured pretest probability estimate in 3 categories: low (<15%), moderate (15% to 40%), and high (>40%), as we have done previously for studies with pulmonary embolism.<sup>7</sup>

## RESULTS

We enrolled 185 patients between November 21, 2006, and June 27, 2007. Two patients voluntarily withdrew from the study (Figure 1) after the completion of the emergency clinician–performed ultrasonography and the reference ultrasonography but before follow-up. We did not record their stated reasons for withdrawal. The 185 emergency clinician–performed ultrasonographic examinations were performed by 56 clinician participants in the following distribution (in descending order): 91 by attending physicians, 45 by postgraduate year (PGY) 3 residents, 20 by PGY-2 residents, 18 by PGY-1 residents, and 11 by midlevel providers. Twenty-eight (15%) emergency clinician–performed ultrasonographs were performed by one of the study authors. Table 1 reports the clinical characteristics of the participating patients. All 185 patients who signed an informed consent form had the reference ultrasonography completed within 6 hours of the emergency clinician–performed ultrasonography, and no patient met the criteria for immediate clinical worsening after emergency clinician–performed ultrasonography.

From the 183 patients who remained in the study for 30 days, the reference standard classified 27 (15%; 95% CI 10% to 21%) patients as deep venous thrombosis(+). No patient had contrast venography done. Radiologists interpreted the initial consultative ultrasonography performed at the index visit as



**Figure 1.** Enrollment process and outcomes of all patient participants. *DVT*, Deep venous thrombosis.

**Table 1.** Clinical characteristics of the 185 patient participants who provided written, informed consent.

Variable	Mean or n	SD or %*
Age, y	51.6	16.1
Body mass index, kg/m <sup>2</sup>	30.6	8.4
Female sex, %	109	59
<b>Race and ethnicity, %</b>		
Asian	1	1
Black	117	63
White	59	32
Hispanic	8	4
<b>Risk factors, %</b>		
History of DVT	25	14
History of PE	8	4
Recent surgery	34	18
Recent hospitalization	50	27
Immobilized	31	17
Cancer	19	10
Smoker	54	29
Pregnant	0	0
Estrogen replacement therapy	8	4
Oral contraceptives	12	6
Alternative diagnosis more likely than DVT (n=148), %		
Musculoskeletal cause	39	21
Cellulitis	32	17
Edema	24	13
Venous insufficiency	17	9
Baker's cyst	7	4
Arthritis	6	3
Congestive heart failure	6	3
Neurologic cause	6	3
Other	11	6

DVT, Deep venous thrombosis; PE, pulmonary embolism.  
\*All percentages use 185 as denominator.

positive for a thrombosis in the popliteal vein or in 1 or more femoral vein(s) in 26 patients, of whom 24 were treated and thus adjudicated to deep venous thrombosis(+). Treatment was not initiated at the index visit for 2 patients who both had an isolated popliteal vein thrombosis. Radiologists also interpreted the initial reference ultrasonography as positive for an isolated saphenous vein thrombosis in 1 patient and positive for isolated calf vein thromboses in 3 patients; none of these 4 patients were treated initially. We completed telephone interview for 156 of 183 (84%) subjects and executed the electronic medical record review process on all 183 patients. The follow-up and adjudication processes revealed that 1 patient with an untreated calf vein thrombosis and 1 patient with an isolated popliteal vein clot were later diagnosed with deep venous thrombosis extension and were treated. One other patient with an initially normal reference ultrasonographic result had a repeated venous ultrasonographic examination that was interpreted by a radiologist as having a positive result, prompting treatment within the 30-day follow-up period. Eight patients died within 30 days of enrollment, including 2 from complications of pulmonary embolism, both of whom were diagnosed with deep venous thrombosis at enrollment and both of whom had a positive emergency clinician-performed ultrasonographic result.

**Table 2.** Diagnostic accuracy of emergency clinician-performed ultrasonography for deep venous thrombosis.

ECPU	Outcome		Total
	DVT(+)	DVT(-)	
Positive*	19	17	36
Negative	8	139	147
<b>Total</b>	<b>27</b>	<b>156</b>	<b>183</b>

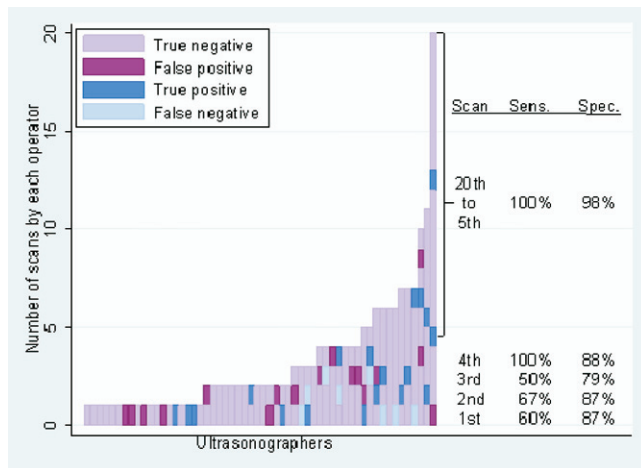
ECPU, Emergency clinician-performed ultrasonography.  
\*Test positive includes 2 indeterminate ECPU examination results, defined as the inability to visualize 1 or more veins. Sensitivity 70% (95% CI 50% to 86%), specificity 89% (95% CI 83% to 94%), diagnostic accuracy 85% (95% CI 79% to 90%), likelihood ratio (positive test) 6.5 (95% CI 3.8 to 10.7); likelihood ratio (negative test) 0.3 (95% CI 0.2 to 0.6).

No patient was diagnosed with pulmonary embolism within 30 days after a negative emergency clinician-performed ultrasonographic result.

Table 2 shows the contingency table used to calculate diagnostic indexes. For calculations, an indeterminate emergency clinician-performed ultrasonographic result was considered a positive test. The average reported degree of difficulty in performing the test ultrasonography was  $3 \pm 3$ , with a median of 2. Five of the 8 false-negative emergency clinician-performed ultrasonographic studies were performed by 2 PGY-3 residents who rated the difficulty in performing each of the examinations above 5. No false-negative emergency clinician-performed ultrasonographic result was obtained in the leg contralateral to the leg with the deep venous thrombosis, according to the reference standard.

Figure 2 plots the results of each emergency clinician-performed ultrasonographic examination in the order it was done by each clinician-participant. The purpose of this figure is to examine for a possible learning effect that might occur as each clinician enrolled more patients studied. Our question was whether diagnostic accuracy improved with experience. The diagnostic accuracy remained relatively constant (approximately 81%) from the first to the third patients enrolled and then increased thereafter. Of particular interest are the 67 patients who were enrolled by 19 clinicians who had already enrolled 3 patients. This group included no false negatives (sensitivity=7/7, or 100%) and had 3 false positives (specificity 57/60, or 95%), leading to a diagnostic accuracy of 64 of 67, or 95.5%.

Table 3 reports the diagnostic accuracy for patients stratified into 6 categories according to the 3 tiers of gestalt pretest probability and the results of the emergency clinician-performed ultrasonography. The posterior probability of deep venous thrombosis was 1 of 88, or 1.1% (0% to 6%), when the clinician's estimate of pretest probability of deep venous thrombosis(+) was low and the same clinician interpreted his or her emergency clinician-performed ultrasonography as negative. The posterior probability of deep venous thrombosis(+) was 11 of 14, or 79% (49 to 95%),



**Figure 2.** Effect of number of patients enrolled by each clinician on the diagnostic accuracy of emergency clinician–performed ultrasonography for deep venous thrombosis. Diagnostic results of each emergency clinician–performed ultrasonography (ECPU) done by each clinician-participant are plotted. Each tile represents a unique clinician-participant (*x* axis) who enrolled a unique patient-participant (*y* axis), and each tile is color coded to show the diagnostic result of the ECPU. The tiles are ordered from left to right in order of least to most patients enrolled per clinician. The tiles stack vertically in temporal order. For example, the clinician to the far right enrolled a total of 20 patients: the first was a false positive, the fourth was a true positive, and the last 7 were true negatives. Diagnostic sensitivity improved to 100% for operators who had enrolled at least 3 previous patients.

when the clinician’s estimate of pretest probability of deep venous thrombosis was high and the same clinician interpreted his or her emergency clinician–performed ultrasonographic results as positive.

## LIMITATIONS

This was a single-center study at a training program with a well-established ultrasonographic curriculum, which could affect generalizability to other EDs. Our results might have been different had we required 50 preliminary examinations, as is recommended by published training requirements for other ultrasonographic examinations, although many ED clinicians routinely perform ultrasonography without having first met published guidelines.<sup>10,11</sup> We did not use consultative bilateral contrast venography as the reference test, which could have led to missed ipsilateral calf vein clots or asymptomatic contralateral deep venous thromboses.<sup>12</sup> Despite an assiduous, fully executed follow-up protocol that included 2 carefully recorded telephone numbers and at least 10 telephone calls on different days at the times the patients suggested, we were unable to complete telephone contact for 15% of our patient population. The clinicians performing ultrasonography were also the evaluating and treating physicians and were responsible for the pretest risk

stratification of these patients. We are unable to determine the potential effects of this interaction on the diagnostic accuracy of emergency clinician–performed ultrasonography. In this article, we did not use a structured pretest probability score for deep venous thrombosis because we sought to capture the clinician–sonographers’ intrinsic belief about the presence of deep venous thrombosis. In a future article, we will compare the performance of previously published structured scoring systems that estimate pretest probability for deep venous thrombosis.

## DISCUSSION

This represents the first study to describe the diagnostic accuracy of single-visit emergency clinician–performed compression venous ultrasonography of the lower extremity in a study conducted on 2 well-defined, relatively large and diverse populations of emergency clinicians and patients. According to the results of our study, we believe that emergency clinician–performed ultrasonography that uses 3-point compression above the calf requires further study and clarification before adoption as a sole method to diagnose and exclude deep venous thrombosis in the ED setting at a single visit.

We believe this study used rigorous methodology. The study design was compliant with the 2 published guidelines for studies of diagnostic accuracy.<sup>13,14</sup> In comparison, when we performed a systematic review of emergency clinician–performed ultrasonography, we found no previously published study that was more than 70% compliant with either guideline.<sup>4</sup> We therefore wrote the present protocol to include the following points that were previously missing in existing literature: inclusion and description of more than 50 emergency clinician sonographers; the use of 3-point compression testing versus 2-point compression protocol (which we believed might increase emergency clinician–performed ultrasonographic sensitivity); documentation of the test performers’ pretest probability, estimates, and detailed clinical characteristics of the patient population; and inclusion of 30-day follow-up and adjudicated outcomes in the reference standard.

Using these methods, we found a lower diagnostic sensitivity and overall accuracy of emergency clinician–performed ultrasonography for detection of deep venous thrombosis than we expected.<sup>4</sup> The present study identifies several important findings that require additional investigation. First, the majority of false-negative emergency clinician–performed ultrasonographic study results were obtained by a few residents who reported the examination to be difficult (rated as more difficult than 5 on an arbitrary scale of 0 to 10 points). Although all examinations were supervised, within the context of a busy urban ED, the degree of supervision could vary. We thus infer a need to examine the effect of the interaction between experience level and the perceived level of difficulty on the diagnostic accuracy of emergency clinician–performed ultrasonography. Second, our number of training studies before enrollment was relatively low and may have been insufficient to produce experience needed for actual clinical practice. Nonetheless, even with these limitations, when combined with

**Table 3.** Outcome frequency of deep venous thrombosis, stratified by pretest probability estimate and result of the emergency clinician–performed ultrasonography.

Pretest Probability	ECPU	Reference Standard			DVT(+)
		DVT(+)	DVT(–)	Subtotal	
Low	Negative	1	87	88	1.1%
	Positive	2	6	8	25%
Moderate	Negative	6	42	48	13%
	Positive	6	8	14	43%
High	Negative	1	10	11	9%
	Positive	11	3	14	79%
Total		27	156	183	15%

pretest probability, our data show that emergency clinician–performed ultrasonography has potential clinical utility. For example, when the clinician had the gestalt impression that the patient had a high pretest probability of deep venous thrombosis and the same clinician interpreted the emergency clinician–performed ultrasonographic result as positive, this combination demonstrated a high positive likelihood ratio (6.5 [95% CI 3.8 to 10.7]). This observation leads to the hypothesis that this combination could be used as part of a clinical protocol to initiate an empiric dose of heparin anticoagulation in anticipation of a consultative ultrasonography. On the other hand, clinicians had the gestalt impression that the patient had a low pretest probability of deep venous thrombosis and interpreted their emergency clinician–performed ultrasonographic results as negative in 88 patients, and only 1 (1.1%; 95% CI 0% to 6%) had deep venous thrombosis(+). This observation leads to the hypothesis that this combination could be used as evidence to allow a patient to be discharged to follow-up for a consultative ultrasonographic evaluation as an outpatient (depending on patient reliability and resource availability).

The potential influence of examiner’s clinical impression and his or her interpretation of the emergency clinician–performed ultrasonography deserves specific comment. In this study, clinicians performed a triple role of assessor of pretest probability of deep venous thrombosis, sonographer, and emergency clinician–performed ultrasonography reader. We infer that the emergency clinician–performed ultrasonographic results were at least partially dependent on the clinician’s belief about the patient’s probability of having deep venous thrombosis. In contrast, most diagnostic studies of imaging or laboratory tests measure the pretest probability independently of the diagnostic test. In that regard, this study represents a divergence from the guidelines published for studies of diagnostic accuracy.<sup>10,11</sup> It remains unknown whether the clinician’s knowledge of the clinical picture improves or worsens the diagnostic accuracy of emergency clinician–performed ultrasonography.

We conclude that single-visit emergency clinician–performed ultrasonography performed by a group of providers with limited training in compression venous ultrasonography of the lower extremity has intermediate diagnostic accuracy. Our findings

raise concern about emergency clinician–performed ultrasonography as a sole method to exclude or diagnose deep venous thrombosis and show the need for further study of the combination and interaction of pretest probability estimation followed by emergency clinician–performed ultrasonography.

*Supervising editor:* David T. Overton, MD, MBA

*Author contributions:* JAK conceived the work, mentored PMO in obtaining funding, supervised the project, performed the primary analysis, and wrote the article. JAK, PMO, VST, GRS, and AMM collected data. PMO, VST, GRS, and AMM participated in article revisions. PMO was the awardee of the funding. VST and GRS directed the training protocol. AMM assisted with training. JAK takes responsibility for the paper as a whole.

*Funding and support:* By *Annals* policy, all authors are required to disclose any and all commercial, financial, and other relationships in any way related to the subject of this article, that might create any potential conflict of interest. See the Manuscript Submission Agreement in this issue for examples of specific conflicts covered by this statement. Supported by a Resident Research Award from the Emergency Medicine Foundation. JAK owns stock in CP Diagnostics, LLC. JAK has received funding from the National Institutes for Health. JAK is the inventor on US Patents 6,575,918; 6,881,193; 7,344,497; and 7,104,964.

*Publication dates:* Received for publication January 8, 2008. Revisions received March 30, 2008, and April 15, 2008. Accepted for publication May 12, 2008.

*Address for reprints:* Jeffrey A. Kline, MD, Emergency Medicine Research, Department of Emergency Medicine, Carolinas Medical Center, PO Box 32861, Charlotte, NC 28323-2861; 704-355-7092, fax 704-355-7047; E-mail jkline@carolinas.org.

## REFERENCES

1. Kahn SR, Solymoss S, Lamping DL, et al. Long-term outcomes after deep vein thrombosis: postphlebotic syndrome and quality of life [review]. *J Gen Inter Med.* 2000;15:425-429.
2. Stevinson BG, Hernandez-Nino J, Rose G, et al. Echocardiographic and functional cardiopulmonary problems 6 months after first-time pulmonary embolism in previously healthy patients. *Eur Heart J.* 2007;28:2517-2524.

3. Stein PD, Hull RD, Patel KC, et al. D-dimer for the exclusion of acute venous thrombosis and pulmonary embolism: a systematic review [review]. *Ann Intern Med.* 2004;140:589-602.
4. Burnside PR, Brown MD, Kline JA. Systematic review of emergency clinician-performed ultrasound for deep venous thrombosis. *Acad Emerg Med.* 2008;15:493-498.
5. Jones AE, Tayal VS, Kline JA. Focused training of emergency medicine residents in goal-directed echocardiography: a prospective study. *Acad Emerg Med.* 2003;10:1054-1058.
6. Moore C, Rose G, Arrowood J, et al. Determination of left ventricular function by emergency physician echocardiography of hypotensive patients. *Acad Emerg Med.* 2002;9:186-193.
7. Runyon MS, Webb WB, Jones AE, et al. Comparison of the unstructured clinician estimate of low clinical probability for pulmonary embolism to the Canadian score or the Charlotte rule. *Acad Emerg Med.* 2005;12:587-593.
8. Kline JA, Mitchell AM, Runyon MS, et al. Electronic medical record review as a surrogate to telephone follow-up to establish outcome for diagnostic research studies in the emergency department. *Acad Emerg Med.* 2005;12:1127-1232.
9. Arkin CF, Wachtel MS. How many patients are necessary to assess test performance? *JAMA* 1990;263:275-280.
10. American College of Emergency Physicians. ACEP emergency ultrasound guidelines—2001. *Ann Emerg Med.* 2001;38:470-481.
11. Moore CL, Gregg S, Lambert M. Performance, training, quality assurance, and reimbursement of emergency physician-performed ultrasonography at academic medical centers. *J Ultrasound Med.* 2004;23:459-466.
12. Sidhu PS, Alikhan R, Ammar T, et al. Lower limb contrast venography: a modified technique for use in thromboprophylaxis clinical trials for the accurate evaluation of deep vein thrombosis. *Br J Radiol.* 2007;80:859-865.
13. Bussuyt PM, Reitsma JBBruns DE, et al. The STARD statement for reporting studies of diagnostic accuracy: explanation and elaboration. *Clin Chem.* 2003;49:7-18.
14. Whiting P, Rutjes AW, Reitsma JB, et al. The development of QUADAS: a tool for the quality assessment of studies of diagnostic accuracy included in systematic reviews. *BMC Med Res Methodol.* 2003;3:25.

**Editor's Capsule Summary:** *What is already known on this topic:* Research has suggested that emergency physician-performed bedside ultrasonography to rule out deep venous thrombosis is a convenient, efficient, and accurate alternative to such studies in the radiology department. *What question this study addressed:* How accurate is a heterogeneous group of emergency clinicians (attending physicians, residents, and midlevel providers) in performing venous ultrasonography for deep venous thrombosis compared with confirmatory ultrasonographic studies performed by the radiology department? *What this study adds to our knowledge:* In 183 patients, 27 of whom had radiologist-confirmed deep venous thrombosis, the emergency department examination was 70% sensitive and 89% specific. *How this might change clinical practice:* The diagnostic accuracy found in this study is less than that previously reported, raising concern about more widespread application of this practice. However, the existence of heterogeneity among operators and improvements with repetition suggest that test performance may be dependent on operator interest and experience.