



## Diagnosics

# Usefulness of hand-held ultrasound devices in out-of-hospital diagnosis performed by emergency physicians

Frédéric Lapostolle MD\*, Tomislav Petrovic MD, Gilles Lenoir MD, Jean Catineau MD, Michel Galinski MD, Jacques Metzger MD, Erick Chanzy MD, Frédéric Adnet MD, PhD

*SAMU 93, UPRES 3409, Université Paris XIII, Hôpital Avicenne, 93009 Bobigny, France*

Accepted 1 July 2005

---

### Abstract

**Objective:** To evaluate the usefulness of ultrasonographic examinations as a diagnostic tool for emergency physicians in out-of-hospital settings.

**Methods:** Prospective study performed in a French teaching hospital.

Eight emergency physicians given ultrasound training for out-of-hospital diagnosis of pleural, peritoneal, or pericardial effusion; deep venous thrombosis; and arterial flow interruption.

After clinical examination, a probability of diagnosis (“clinical score”) was assigned on visual analog scale from 0 (absent lesion) to 10 (present lesion). Clinical score between 3 and 7 was considered as clinically doubtful. After ultrasound examination, a second probability (“ultrasound score”) was similarly determined. Potential usefulness of ultrasound examination was evaluated by calculating the absolute difference between clinical and ultrasound scores. Patients were followed up to determine final diagnosis: present or absent lesion. “Ultrasound usefulness score” (USS) was determined attributing a positive (when ultrasonography increased diagnostic accuracy) or a negative (when ultrasonography decreased diagnostic accuracy) value to the absolute difference between clinical and ultrasound scores.

**Results:** One hundred sixty-nine patients were included and 302 ultrasound examinations performed. Median duration of examination was 6 minutes (5–10 minutes). The suspected lesion was found in 45 cases (17%). Mean USS was +2 (0–4). Ultrasonographic examination improved diagnostic accuracy (ie, positive USS) in 181 (67%) cases, decreased it (ie, negative USS) in 22 (8%) cases, and was not contributive (ie, USS was 0) in 67 (25%) cases. When initial diagnosis was uncertain (n = 115), diagnostic performance reached +4 (3–5) and ultrasonographic examination improved diagnostic accuracy in 103 (90%) cases.

**Conclusion:** Out-of-hospital ultrasonography increased diagnostic accuracy in out-of-hospital settings. © 2006 Elsevier Inc. All rights reserved.

---

---

\* Corresponding author. Tel.: +33 1 48 96 44 55; fax: +33 1 48 96 44 45.  
E-mail address: frederic.lapostolle@avc.ap-hop-paris.fr (F. Lapostolle).

## 1. Introduction

Technological advances now permit the use of ultrasonography in routine examination. Nowadays, emergency physicians currently perform ultrasonographic examinations in the emergency department, particularly in trauma patients. Such practice has been shown to increase diagnosis accuracy and to optimize patient care [1-3]. Emergency physicians now have hand-held ultrasound devices at their disposal to perform ultrasonographic examinations in out-of-hospital settings [4,5]. Development of such a new diagnostic technique in prehospital settings required to study its feasibility and to validate emergency physician training. Feasibility has been previously demonstrated [6]. We also recently validated a model of theoretical and practical training for emergency physicians in our out-of-hospital emergency department [7]. Nevertheless, the usefulness of ultrasonographic examinations in out-of-hospital clinical practice has to be established.

## 2. Objective

The aim of this study was to evaluate the usefulness of ultrasonographic examinations as a diagnostic tool for emergency physicians in out-of-hospital settings.

## 3. Materials and methods

This prospective study took place in a French teaching hospital from March 2001 to June 2003. In France, out-of-hospital medical emergencies are managed by the Service d'Aide Médicale Urgente [8]. There is a national telephone number to contact the regional emergency physician dispatcher of the Service d'Aide Médicale Urgente 24 hours a day. Seven ambulances carrying an emergency physician,

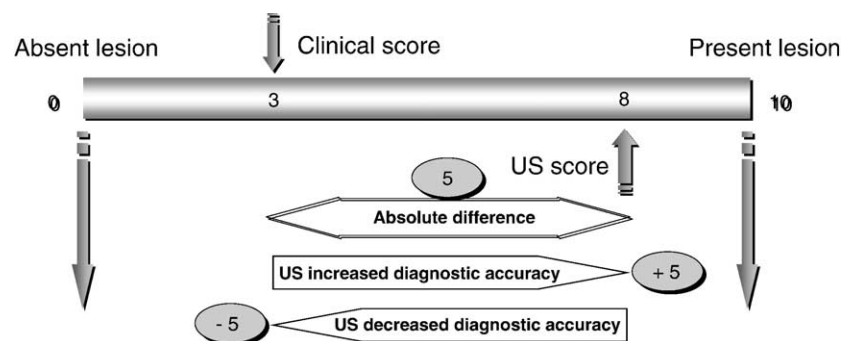
a nurse, and a trained driver are available within our region and sent on site by the dispatcher.

Eight emergency physicians were given ultrasound training. The syllabus of the ultrasound training course has been previously detailed. This tutorial was focused on diagnosis of pleural, peritoneal, or pericardial effusion and vascular disease (deep venous thrombosis or arterial flow interruption). When such diagnoses were suspected, out-of-hospital ultrasound examination was performed using a hand-held ultrasound device with a 3.5-MHz transducer probe (Sonosite 180, Sonosite France, Lyon, France).

Circumstances of intervention, age, and sex of the patients were prospectively recorded. Diagnostic accuracy was evaluated using visual analog scale (VAS) using a similar method as in a previously published study [5]. Emergency physicians performed a clinical examination and assigned a probability of diagnosis called "clinical score" on the VAS (Fig. 1). The VAS was graduated from 0 corresponding to a normal examination (ie, absence of lesion) to 10 corresponding to an identified lesion. A clinical score between 3 and 7 was considered as a clinically doubtful situation. After ultrasound examination (whose duration was recorded), emergency physicians determined a second probability called "ultrasound score." This score used the same VAS graduated from 0 (absence of lesion) to 10 (identified lesion) (Fig. 1). The absolute difference between clinical and ultrasound scores was calculated, corresponding to the potential diagnostic usefulness of ultrasonography (Fig. 1).

Patients were followed up to determine the presence or the absence of the suspected lesion. This diagnosis was established by in-hospital ultrasound examination, computed tomographic scan, surgery, or according to patients' final diagnosis on discharge.

The "ultrasound usefulness score" (USS) was determined attributing a positive or a negative value to the absolute difference between clinical and ultrasound scores depending on the positive or negative influence of ultrasonography on diagnosis accuracy (Fig. 1). When ultrasonographic examination



**Fig. 1** Scoring example: emergency physician assigned a first probability of diagnosis after clinical examination (clinical score) using a VAS graduated from 0 (absent lesion) to 10 (present lesion) (3 in the example) and a second probability after ultrasound examination ("US score") on the same VAS (8 in the example). The absolute difference between clinical and US scores was calculated to evaluate potential influence of US on diagnostic accuracy (5 in this example). Final diagnosis (present or absent lesion) was obtained by in-hospital follow-up. When US examination had increased diagnostic accuracy, a positive value was attributed to the absolute difference (+5 in the example), and when US examination had decreased diagnostic accuracy, a negative value was attributed (-5 in the example).

**Table 1** Ultrasonographic examination performed in out-of-hospital settings by an emergency physician

Suspected lesion	N	(%)
Peritoneal effusion	143	47
Pleural effusion	86	29
Pericardial effusion	16	5
Vascular lesions	35	12
Other indication	22	7
Total	302	100

increased diagnosis accuracy, that is, when the ultrasound score was closer to the final diagnostic than the clinical score, a positive value was attributed. In the opposite case, when ultrasonographic examination decreased diagnosis accuracy, that is, when the clinical score was closer to the final diagnostic than the ultrasound score, a negative value was attributed. Results are expressed as median (25th-75th percentiles).

### 4. Results

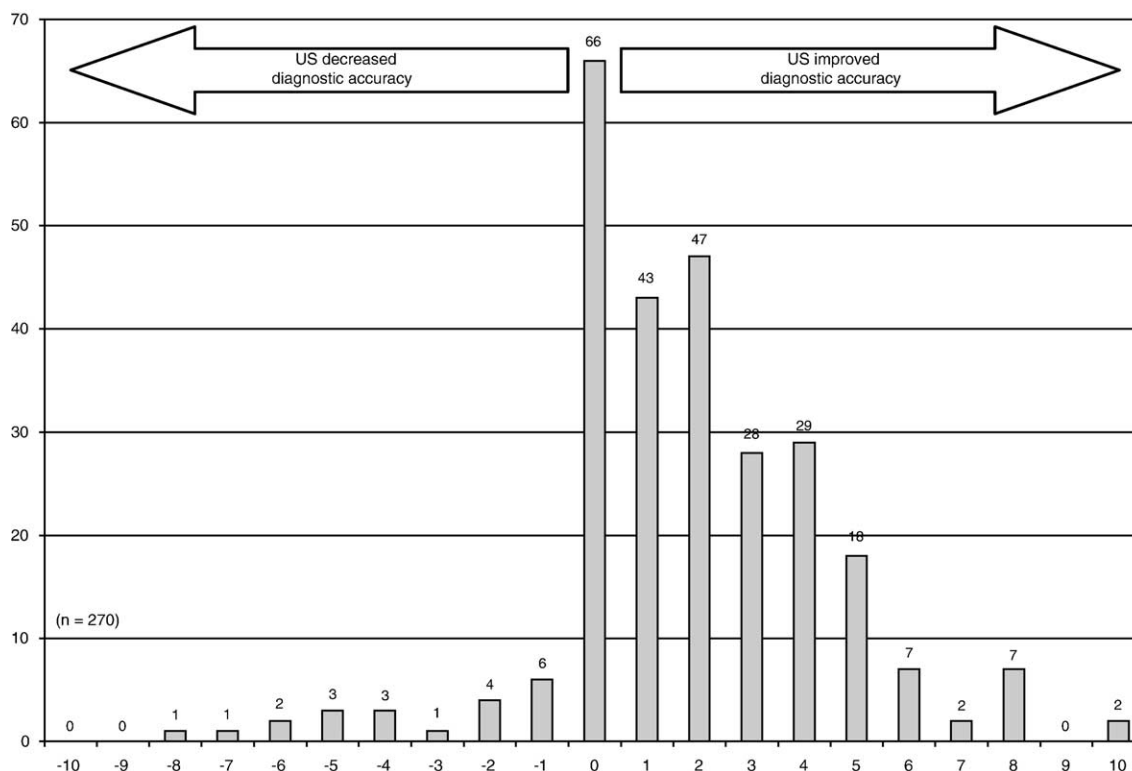
One hundred sixty-nine patients were included in this study and 302 ultrasound examinations were performed. The median duration of examination was 6 minutes (5-10 minutes) for each patient. Final diagnosis was available in 158 (93%) patients as 5% were lost to follow-up and 2% died before final diagnosis was established. The distribution of examinations performed is summarized in Table 1.

**Table 2** Ultrasonographic examination performed in out-of-hospital settings by an emergency physician: diagnostic performance and median score according to clinical score

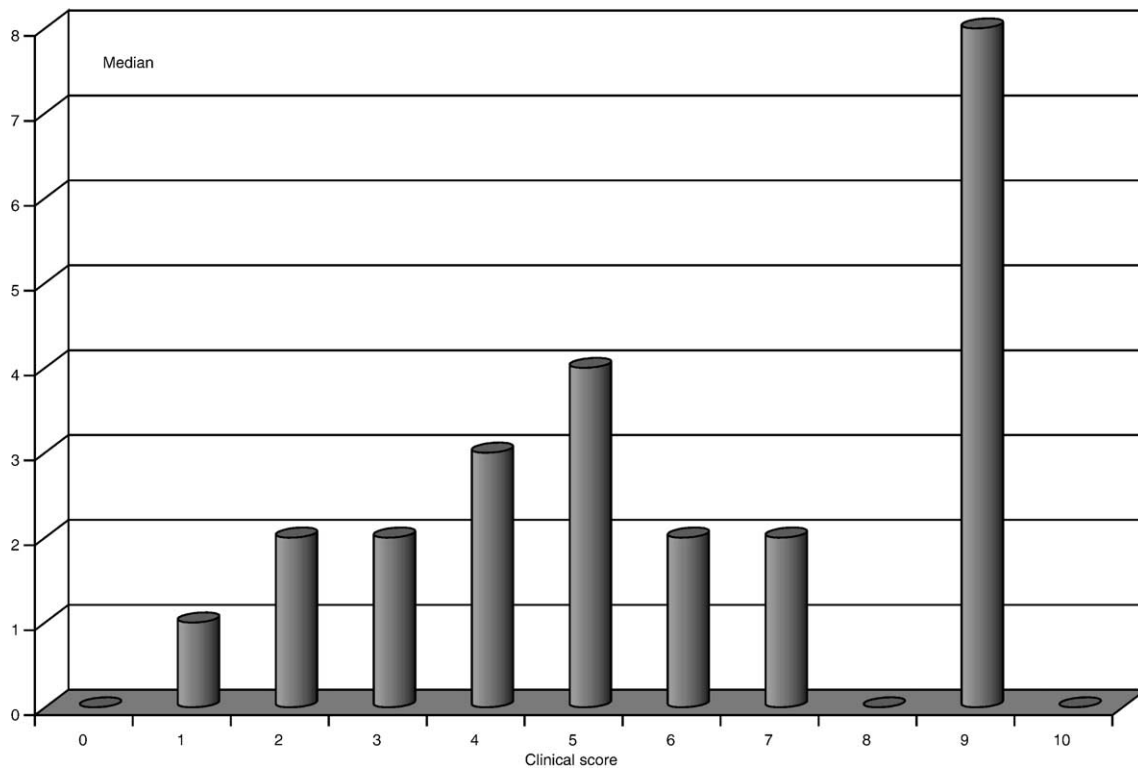
Diagnostic performance					
Clinical score	n	Positive	Zero	Negative	Median (25th-75th percentiles)
		n (%)	n (%)	n (%)	
0	36	3 (8)	30 (83)	3 (8)	0 (0-0)
1	54	30 (56)	22 (41)	2 (4)	1 (0-1)
2	43	33 (77)	5 (12)	5 (12)	2 (1-2)
3	25	22 (88)	0 (0)	3 (12)	2 (2-3)
4	23	21 (91)	1 (4)	1 (4)	3 (3-4)
5	45	42 (93)	2 (4)	1 (2)	4 (4-5)
6	11	8 (73)	0 (0)	3 (27)	2 (0-5)
7	11	10 (91)	0 (0)	1 (9)	2 (2-5)
8	13	8 (62)	3 (23)	2 (15)	0 (1-7)
9	4	3 (75)	0 (0)	1 (25)	8 (5-8)
10	5	1 (20)	4 (80)	0 (0)	0 (0-2)
Total	270	67 (25)	22 (8)	181 (67)	0 (0-3)

Diagnostic performance score was positive when ultrasonographic examination improved diagnostic accuracy; was negative when ultrasonographic examination decreased diagnostic accuracy; and was zero when ultrasonographic examination was not contributive.

A total of 270 ultrasound examinations were studied in these 158 patients. A lesion was finally diagnosed in 45 cases (17%). The mean USS was +2 (0-4). Ultrasound usefulness score was positive (ie, ultrasonographic examination



**Fig. 2** Diagnostic performance score from -10 (negative when ultrasonographic [US] examination decreased diagnostic accuracy) to +10 (positive when US examination improved diagnostic accuracy).



**Fig. 3** Median of performance score according to clinical score.

improved diagnostic accuracy) in 181 (67%) cases; was negative (ie, ultrasonographic examination decreased diagnostic accuracy) in 22 (8%) cases; and was zero (ie, ultrasonographic examination was not contributive) in 67 (25%) cases (Fig. 2). Details of USS according to clinical score are reported in Table 2 and Figs. 3 and 4. This performance reached +4 (3-5) when clinical score was between 3 and 7 (ie, when clinical evaluation was doubtful) ( $n = 115$ ). In this subgroup, USS was positive in 103 (90%) cases, negative in 9 (7%) cases, and zero in 3 (3%) cases.

## 5. Discussion

Out-of-hospital ultrasonography significantly increased diagnostic performance in this out-of-hospital study. Technological advances now permit the use of ultrasonography in routine examination in the emergency department, particularly in trauma patients. Ultrasound examination indications are increasing as it is a noninvasive technique. Recently, portable echocardiography has been considered as “essential for the management of acutely ill patients” [9].

Out-of-hospital use of such hand-held ultrasound devices was unavoidable in France, where out-of-hospital emergencies are managed by emergency physicians [8]. The ultrasonography device used in our study (Sonosite 180) is small ( $30 \times 19 \times 6$  cm), lightweight (2.4 kg with the 3.5-MHz probe), and has a prolonged battery life and an excellent quality of image, making it ideal for out-of-hospital use.

In most cases, especially in cases of uncertain clinical diagnosis (Figs. 3 and 4), ultrasonographic examination increased diagnostic accuracy. Ultrasonography as a diagnostic help has previously been reported in hospital studies [2,3,10]. Early diagnosis (ie, out-of-hospital diagnosis) is precious as it can contribute to optimize patient care. Furthermore, according to the French out-of-hospital emergency care organization [8], early diagnosis is precious as it can contribute to accelerate and optimize patient orientation.

This strategy, when combined with prehospital ultrasonographic examination, was not time-consuming in our study. This parameter has to be integrated in ultrasonographic evaluation, particularly in trauma patients and/or in out-of-hospital studies. Indeed, in trauma patients, transport to hospital with a surgical unit should not be delayed. To save time, indications for ultrasonography examination, as well as examination procedures, have to be previously and clearly established. In our study, ultrasonographic examination was performed to answer simple questions such as “is there peritoneal effusion or not?” Thus, time duration of examination was short.

According to previously published studies, examinations performed to diagnose peritoneal and/or pleural effusion were the most frequent. Use of ultrasonography to diagnose intraperitoneal liquid effusion has been largely studied. The Focused Assessment for Sonography in Trauma has been largely validated in trauma patients, including in studies performed with hand-held devices [11]. Hand-held ultrasound devices are incorporated into routine bedside

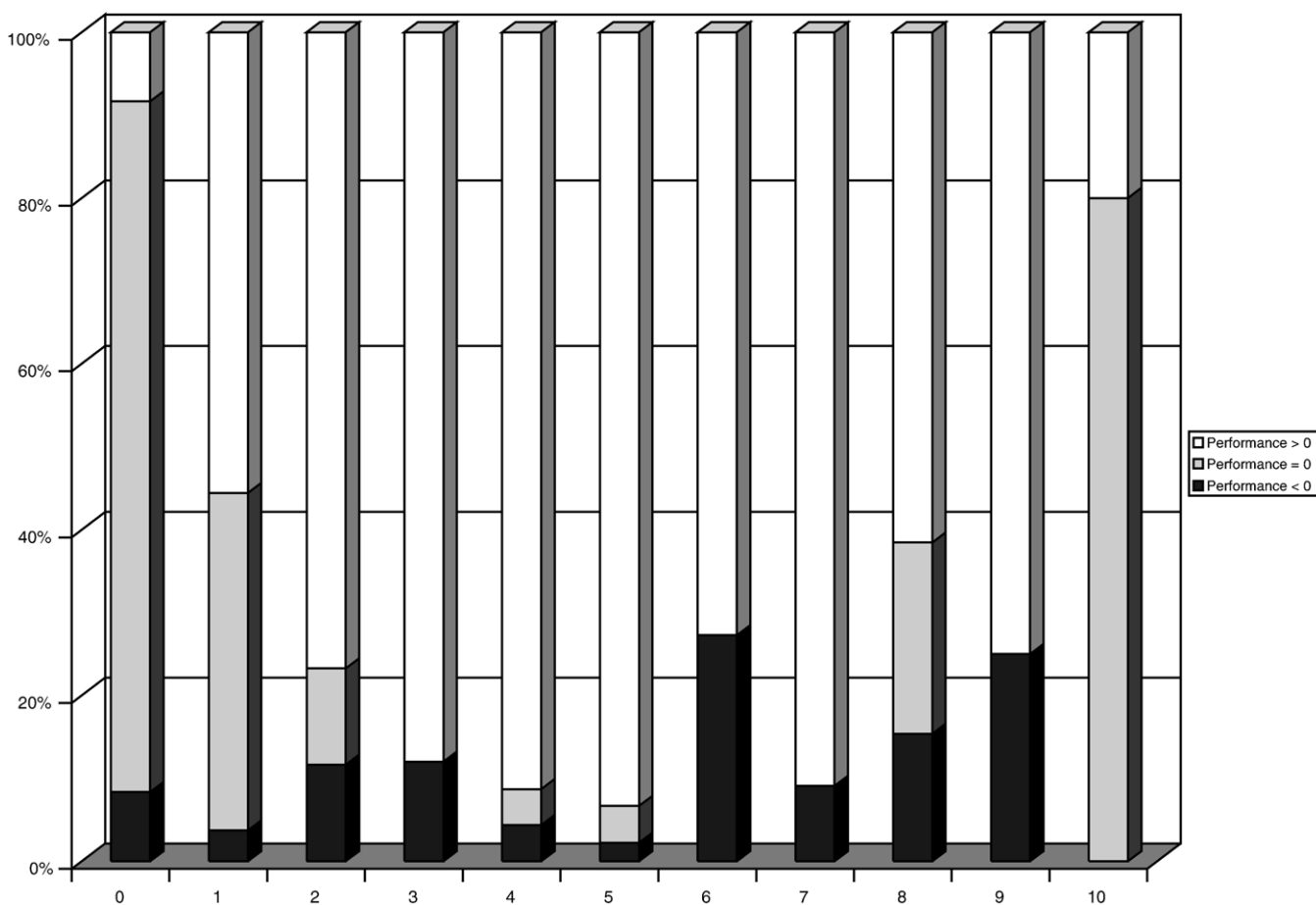


Fig. 4 Repartition of performance score (negative, positive, or zero) according to clinical score.

examination. It should therefore be considered as a routine diagnostic help and evaluated as such. Usual evaluation is based on criteria such as sensitivity, specificity, and predictive values. This binary approach is the corner stone of a classical assessment but does not take into account the clinical usefulness of this tool.

This is well illustrated with auscultation usefulness. Auscultation does not give a definitive diagnosis by itself but, incorporated into a global evaluation of the patient, contributes to a better diagnostic accuracy. Similarly, our results demonstrated that ultrasonographic examination contributed to increase diagnostic accuracy, particularly in uncertain clinical situation. This is the real usefulness of ultrasonography in out-of-hospital settings. From now on, ultrasonography should play a crucial role in the establishment of out-of-hospital diagnosis.

Using the same analog methods we used, Kimura et al [5] recently demonstrated that hand-held ultrasonography strongly contributed to improve diagnostic accuracy of left ventricular dysfunction.

Many other indications for out-of-hospital ultrasonographic diagnosis examination are currently proposed. Thoracic examination (searching for pleural or pericardial effusion), vascular examination (searching for deep venous thrombosis, arterial flow interruption, aortic aneurysm or

dissection), cardiac examination (searching for left or right ventricular failure), bone examination (searching for fracture), and pelvic examination (searching for pregnancy, in utero or not) are the most evaluated of these potential diagnostic indications. Most of them are promising for out-of-hospital use.

But, all in all, ultrasonography examination increased diagnosis accuracy in our study. As ultrasonographic examination is available, easy, and fast to perform, it can be used to monitor patients and can be repeated during transportation of patients [4]. This is crucial to optimize out-of-hospital ultrasonographic examination. Indeed, in trauma patients, complications such as peritoneal effusion due to liver or bladder lesion are sometimes delayed. When the first examination is performed too early in the course of the disease, an effusion could be too small to be diagnosed. In practice, to avoid false-negative result, ultrasonographic examination has to be repeated. In this study, as we compared initial diagnosis before and after ultrasonographic examination with the final diagnosis, such procedure was not done. Then, we cannot exclude that some false-negative results were in fact delayed lesions such as peritoneal effusions.

It should be noted that, because of the design of the study, technical difficulties such as inadequate patient

access, poor quality of examination, or difficult screen visualization because of ambient luminosity sometimes happened. These limiting factors probably contributed to attenuate the performance of ultrasonography, but, in contrast, the performance reported reflected the usefulness of ultrasonography “in the real world.” For similar reasons, we did not exclude first examinations performed by each emergency physician, whereas it is well known that performance is poor at the beginning of the training. Then, in the real world, with experienced operators, results should be better than they appeared in this study.

## 6. Conclusion

Out-of-hospital ultrasonography significantly increased diagnostic performance in this out-of-hospital study. This strategy was not time-consuming. Examinations performed to diagnose peritoneal and/or pleural effusion were the most frequent, but other indications should be specifically evaluated in out-of-hospital settings.

## References

- [1] Plummer D, Brunette D, Asinger R, Ruiz E. Emergency department echocardiography improves outcome in penetrating cardiac injury. *Ann Emerg Med* 1992;21:709-12.
- [2] Glaser K, Tschmelitsch J, Klingler P, Wetscher G, Bodner E. Ultrasonography in the management of blunt abdominal and thoracic trauma. *Arch Surg* 1994;129:743-7.
- [3] Boulanger BR, McLellan BA, Brenneman FD, et al. Emergent abdominal sonography as a screening test in a new diagnostic algorithm for blunt trauma. *J Trauma* 1996;40:867-74.
- [4] Polk JD, Fallon Jr WF, Kovach B, Mancuso C, Stephens M, Malangoni MA. The Airmedical “F.A.S.T.” for trauma patients—the initial report of a novel application for sonography. *Aviat Space Environ Med* 2001;72:432-6.
- [5] Kimura BJ, Amundson SA, Willis CL, Gilpin EA, DeMaria AN. Usefulness of a hand-held ultrasound device for bedside examination of left ventricular function. *Am J Cardiol* 2002;90:1038-9.
- [6] Lapostolle F, Petrovic T, Catoire J, Garcia S, Adnet F. Out-of-hospital ultrasonographic diagnosis of left ventricular wound after penetrating thoracic trauma. *Ann Emerg Med* 2004;43:422.
- [7] Lapostolle F, Petrovic T, Catoire J, Lenoir G, Adnet F. Training emergency physician to perform out-of-hospital ultrasonography. *Am J Emerg Med* 2005;23:572.
- [8] Nikkanen HE, Pouges C, Jacobs LM. Emergency medicine in France. *Ann Emerg Med* 1998;31:116-20.
- [9] Ashrafian H, Bogle RG, Rosen SD, Henein M, Evans TW. Portable echocardiography. *BMJ* 2004;328:300-1.
- [10] Boulanger BR, McLellan BA, Brenneman FD, Ochoa J, Kirkpatrick AW. Prospective evidence of the superiority of a sonography-based algorithm in the assessment of blunt abdominal injury. *J Trauma* 1999;47:632-7.
- [11] Kirkpatrick AW, Simons RK, Brown R, Nicolaou S, Dulchaysky S. The hand-held FAST: experience with hand-held trauma sonography in a level-I urban trauma center. *Injury* 2002;33:303-8.