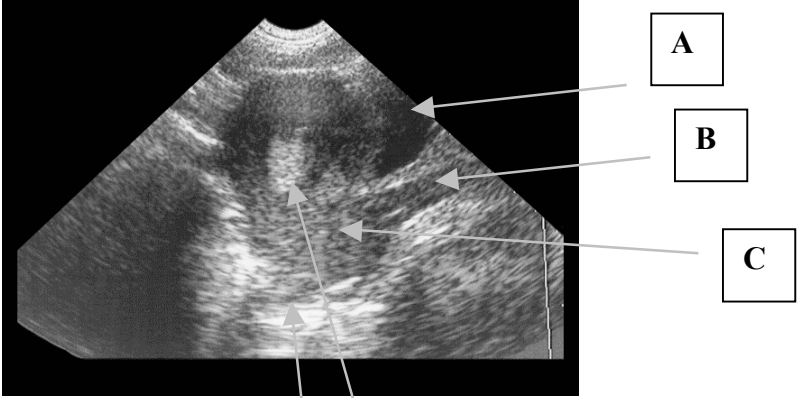


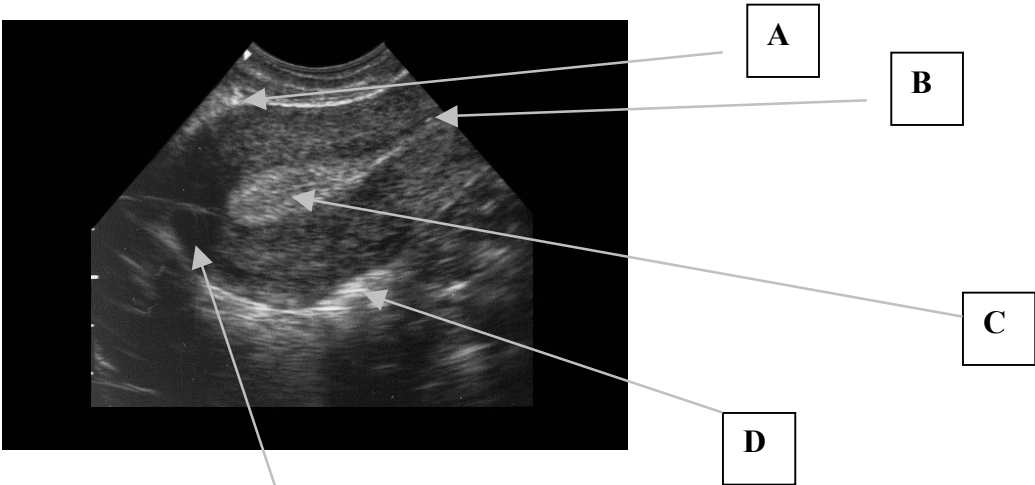
SLRHC Credentialing Examination
Pelvic



Identify:

- A. _____
- B. _____
- C. _____
- D. _____
- E. _____

F. This is a TRANSABDOMINAL/TRANSVAGINAL image.



Identify:

- A. _____
- B. _____
- C. _____
- D. _____
- E. _____

F. This is a TRANSABDOMINAL/TRANSVAGINAL image.

Please circle the single best answer:

- 1) The main indication for emergency sonography in 1st trimester pregnancy is to confirm:
 - A) Intrauterine pregnancy
 - B) Ovarian torsion
 - C) Fluid in the cul de sac
 - D) Ectopic pregnancy
 - E) Corpus lustrum cyst

- 2) A patient presents with a positive urine pregnancy test and vaginal bleeding in the 1st trimester. She is hemodynamically stable and a bedside emergency pelvic ultrasound is indeterminate. The next best step is:
 - A) Repeat bedside ultrasound in 30 min
 - B) Obtain a formal ultrasound and OB/Gyn consultation
 - C) Wait the results of the serum HCG to determine the next step
 - D) Discharge the patient home with instructions
 - E) Culdocentesis

- 3) The most common site for pooling of pelvic free fluid is:
 - A) Ano-rectal recess
 - B) Splenorenal recess
 - C) Hepatorenal recess
 - D) Anterior cul de sac
 - E) Posterior cul de sac

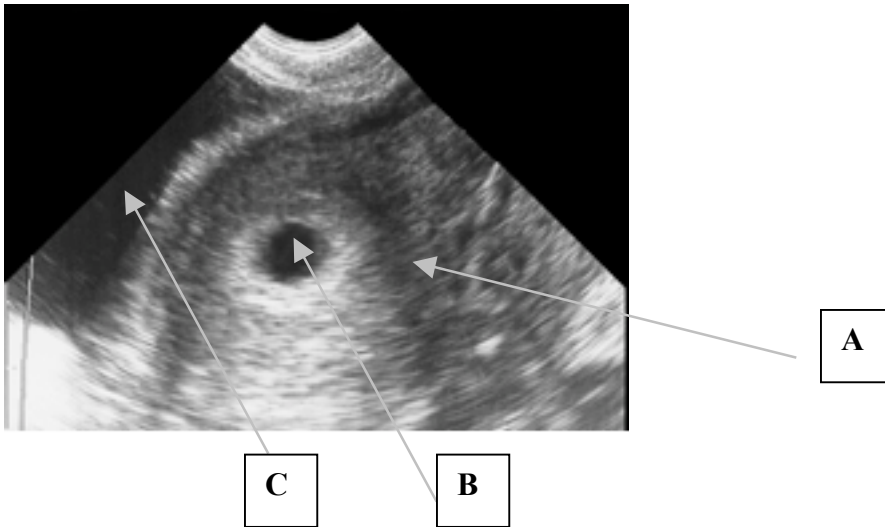
- 4) Transabdominal sonography of the uterus is best accomplished by a HIGH/LOW frequency probe.

- 5) Transvaginal sonography of the uterus is best accomplished by a HIGH/LOW frequency probe.

- 6) For optimal transabdominal pelvic ultrasound imaging, the bladder should be FULL/EMPTY.

- 7) For optimal transvaginal pelvic ultrasound imaging, the bladder should FULL/EMPTY.

- 8) Which agent is best for lubricating the outside sheath of a probe for vaginal sonography?
 - A) Conducting gel
 - B) Water-based lubricant
 - C) Bacitracin ointment
 - D) Sterile H₂O
 - E) None



Identify:

- A. _____
 B. _____
 C. _____

D. This is a TRANSVAGINAL/TRANSABDOMINAL image. (Circle)

9) In relation to the iliac vessels, the ovary is anatomically located:

- A) Medial and posterior
 B) Medial and anterior
 C) Lateral and posterior
 D) Lateral and anterior
 E) No relationship

10) Which is the correct progression of pregnancy as visualized by pelvic sonography?

- A) Intradecidual sign, yolk sac, gestational sac, embryo with cardiac activity
 B) Intradecidual sign, gestational sac, yolk sac, embryo with cardiac activity
 C) Gestational sac, embryo with cardiac activity, yolk sac, intradecidual sign
 D) Gestational sac, intradecidual sign, embryo with cardiac activity, yolk sac
 E) Yolk sac, embryo with cardiac activity, gestational sac, intradecidual sign

11) True/False An empty uterus with an HCG < 1000 mIU/mL has low suspicion for ectopic pregnancy.

12) True/False According to SLR credentialing criteria, a clear double decidual sign is the first reliable evidence of an IUP.

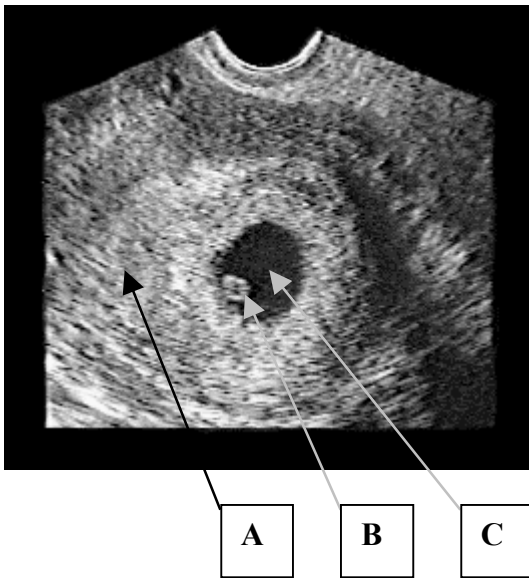
13) True/False According to SLR credentialing criteria, cardiac activity in the uterus in the embryo is the best evidence of an IUP.

14) True/False Patients on fertility medication have increased risk of a heterotopic with an IUP.

15) True/False Patients should be informed that emergency bedside ultrasound is a screening tool only and is not designed to detect most embryonic abnormalities.

16) A pregnancy implanted on the margin of the uterine wall and not in the cavity is:

- A) Corpus luteum cyst
- B) Hydatidiform mole
- C) Intrauterine pregnancy
- D) Interstitial ectopic pregnancy
- E) Blighted ovum



Identify:

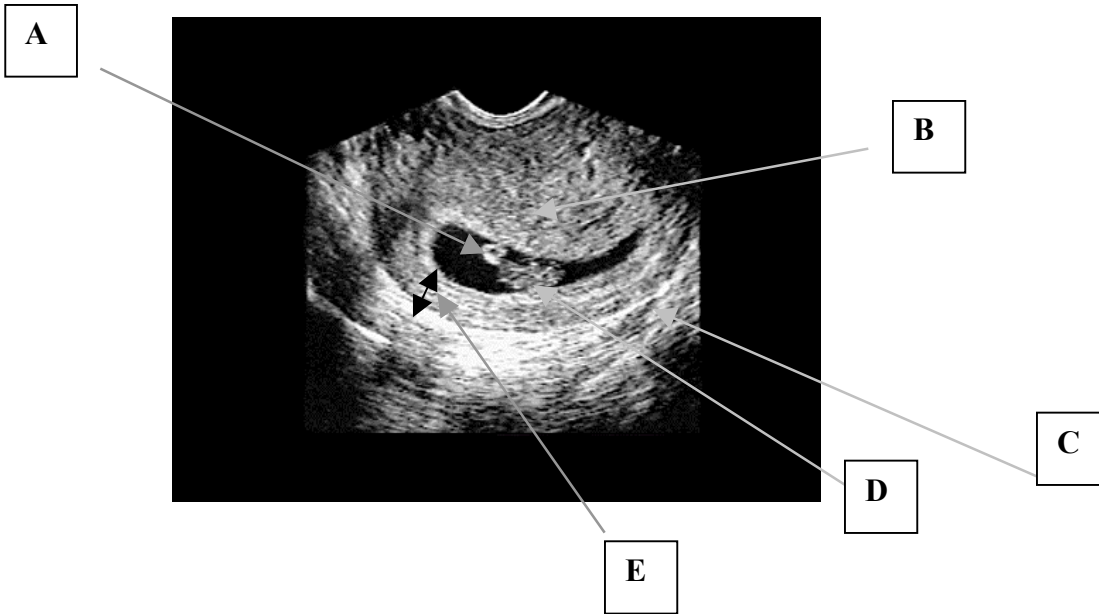
A) _____

B) _____

C) _____

D) This is a TRANSABDOMINAL/TRANSVAGINAL IMAGE

E) True/False This documents an early IUP.



Identify:

- A. _____
- B. _____
- C. _____
- D. _____
- E. _____

This is a TRANSABDOMINAL/TRANVAGINAL IMAGE
 True/False This documents an early IUP.

17) All of the following are risk factors for ectopic pregnancy except:

- A) IUD
- B) History of ectopic
- C) PID
- D) Early menarche
- E) Bilateral tubal ligation

18) The most common pelvic mass seen in early pregnancy is:

- A) Thecal lutein cyst
- B) Dermoid cyst
- C) Uterine leiomyoma
- D) Hydatiform mole
- E) Corpus luteum cyst

- 19) The typical probe frequency for transabdominal pelvic sonography:
- A) 1 -3 MHz
 - B) 3.5-5 MHz
 - C) 5-7.5 MHz
 - D) 9-11 MHz
 - E) 20 MHz
- 20) The typical probe frequency for transvaginal pelvic sonography:
- A) 1 -3 MHz
 - B) 3.5-5 MHz
 - C) 5-7.5 MHz
 - D) 9-11 MHz
 - E) 20 MHz
- 21) An empty gestational sac (no yolk sac or embryo) measuring 20mm or larger is commonly called:
- A) Corpus luteum cyst
 - B) Hydatiform mole
 - C) Dermoid cyst
 - D) Blighted ovum
 - E) Early IUP
- 22) A normal fetal heart rate for a 1st trimester pregnancy:
- A) 60
 - B) 110
 - C) 160
 - D) 240
 - E) 300
- 23) All of the following causes of pelvic pain should be considered in 1st trimester pregnancy once an intrauterine pregnancy is confirmed EXCEPT:
- A) Pericardial effusion
 - B) Ovarian torsion
 - C) Appendicitis
 - D) Renal calculus
 - E) Ligamentous strain