

---

# The Effect of Soft-tissue Ultrasound on the Management of Cellulitis in the Emergency Department

Vivek S. Tayal, MD, Nael Hasan, MD, H. James Norton, PhD, Christian A. Tomaszewski, MD

---

## Abstract

**Objectives:** To evaluate the effect of diagnostic soft-tissue ultrasound (US) on management of emergency department (ED) patients with clinical cellulitis.

**Methods:** This was a prospective observational study in an urban ED of adult patients with clinical soft-tissue infection without obvious abscess. The treating physician's pretest opinions regarding the need for further drainage procedures and the probability of subcutaneous fluid collection were determined. Emergency sonologists then performed US of the infected area, and the effect on management plan was recorded.

**Results:** Ultrasound changed the management of patients with cellulitis in 71/126 (56%) of cases. In the pretest group that was believed *not* to need further drainage, US changed the management in 39/82 (48%), with 33 receiving drainage and 6 receiving further diagnostics or consultation. In the pretest group in which further drainage was believed to be needed, US changed the management in 32/44 (73%), including 16 in whom drainage was eliminated and 16 who had further diagnostic interventions. US had a management effect in all pretest probabilities for fluid from 10% to 90%.

**Conclusions:** Soft-tissue US changes physician management in approximately half of patients in the ED with clinical cellulitis. US may guide management of cellulitis by detection of occult abscess, prevention of invasive procedures, and guidance for further imaging or consultation.

ACADEMIC EMERGENCY MEDICINE 2006; 13:384–388 © 2006 by the Society for Academic Emergency Medicine

**Keywords:** ultrasound, soft-tissue, cellulitis, emergency, management, abscess

---

Soft-tissue infection commonly encompasses clinical entities from cellulitis to frank abscess.<sup>1</sup> Differentiating the type of soft-tissue infection and then choosing the appropriate therapy can be difficult clinically without clear findings of abscess.<sup>2</sup> Ultrasound (US) has been found to be an accurate tool by emergency physicians and other groups for the detection of cutaneous abscess.<sup>3–6</sup> The role of US in patients with clinical cellulitis

or soft-tissue infection without abscess has not been defined. We evaluated the effect of diagnostic soft-tissue US on management of emergency department (ED) patients with clinical cellulitis.

## METHODS

### Study Design

This was a prospective, observational study on the effect of bedside soft-tissue US on emergency physicians' management of ED patients with clinical cellulitis without obvious abscess. This study was approved by the institutional review board. Prospective written informed consent was obtained from all patients.

### Study Setting and Population

The study took place over 28 months at an urban, regional ED that receives approximately 100,000 patient visits per year. An emergency medicine department of 20 attending faculty physicians, 30 emergency medicine residents, and 5 physician assistants provides initial care to all emergency patients.

---

From the Department of Emergency Medicine (VST, NH, CAT), Department of Biostatistics (HJN), Carolinas Medical Center, Charlotte, NC.

Dr. Hasan is currently at Lynchburg General Hospital, Lynchburg, VA.

Received October 15, 2005; revision received November 17, 2005; accepted November 22, 2005.

Presented at the Annual Meeting of the Society for Academic Emergency Medicine in Boston, MA, May 2003.

Address for correspondence and reprints: Vivek S. Tayal, MD, Department of Emergency Medicine—CMC, Box 32861, Charlotte, NC 28232. Fax: 704-355-7047; e-mail: vtayal@carolinas.org.

Inclusion criteria for the study required all of the following: 1) age  $\geq$  18 years, 2) evidence of cutaneous soft-tissue infection (typically elements including erythema, induration, warmth, or tenderness), and 3) no signs of obvious abscess in the judgment of the treating emergency physician. Obvious abscess was clinician defined but typically was an area of cutaneous soft-tissue infection with fluctuance, drainage, skin elevation, or other signs of subcutaneous purulence by physical examination. Perineal infections were excluded.

### Study Protocol

Upon identification of an eligible patient, informed consent and demographic data were obtained. Two separate pretest (pre-US) questions were asked of the treating physician: 1) pretest opinion regarding the need for further drainage procedures, as determined by a yes–no question and 2) the pretest probability for the presence of a subcutaneous fluid collection via a scale from 0 to 100 in 10-point scale increments (0 = no chance and 100 = complete confidence of subcutaneous fluid).

The soft-tissue US was performed by a core group of five emergency physician investigators with significant experience (>100 total examinations) in typical uses of emergency US. These investigators were trained in soft-tissue ultrasonography by the emergency US director and performed at least five soft-tissue US before enrollment of study patients. This number was chosen to reflect the typical emergency sonologist's experiential level with a novel application, such as soft-tissue infection.

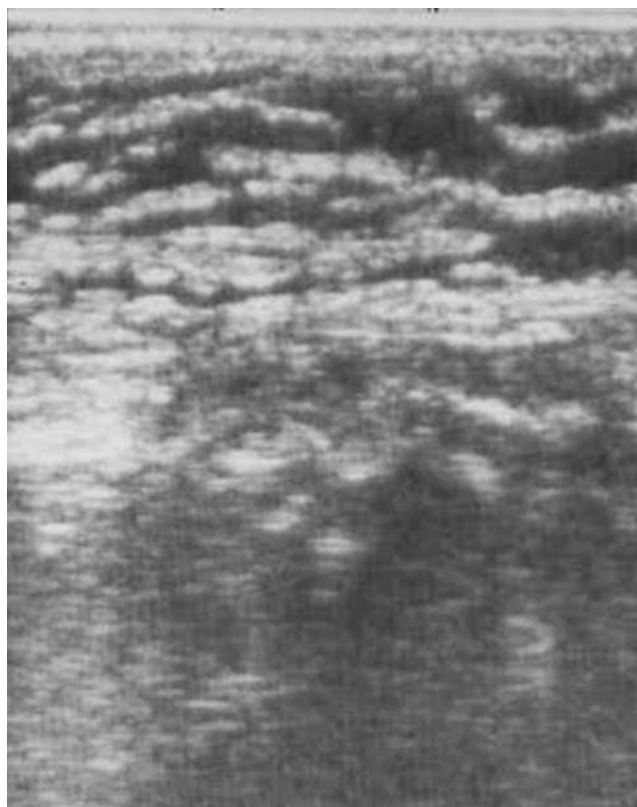
Two Shimadzu (Kyoto, Japan) grey-scale 400 and 450 model US machines with high-frequency (7.5-MHz modal) linear probes were used for investigation of subcutaneous infection. Abdominal (3.5-MHz modal) probes were available for deep collections or wider views to supplement the standard linear probe investigation.

The US technique included movement of the probe over the affected area from normal skin to affected skin in two orthogonal planes to provide comparison and gauge extent of subcutaneous fluid. An abscess was defined sonographically as an irregular anechoic or hypoechoic collection with varying degrees of echogenic fluid. Any such abscesses were evaluated in real-time scanning in regard to size, extent, echogenicity, and comparison to normal or cellulitic tissue.<sup>7,8</sup> Cellulitis was identified sonographically by hyperechoic fat lobules with fluid-filled interlobar septae typical of subcutaneous edema.<sup>7</sup> Figure 1 and Figure 2 show typical US findings of cellulitis and abscess, respectively.

The US images and interpretation were revealed to the treating physician, and the effect of the US results on the management plan was recorded. Effect on management was recorded as *no effect*, *new drainage procedure*, *elimination of drainage procedure*, *consultation*, *further imaging*, *procedural guidance*, or *other*. Ultrasound guidance, either dynamic or static, was allowed for any invasive procedure.

### Measures

The primary outcome measure was the effect of soft-tissue US on the management of clinical cellulitis by the patient's primary emergency physician. Secondary



**Figure 1.** Ultrasound image of cellulitis showing subcutaneous fluid surrounding hyperechoic fat lobules.

end-points included the effect of US on management, stratified by pretest probability for presence of a subcutaneous fluid collection.

### Data Analysis

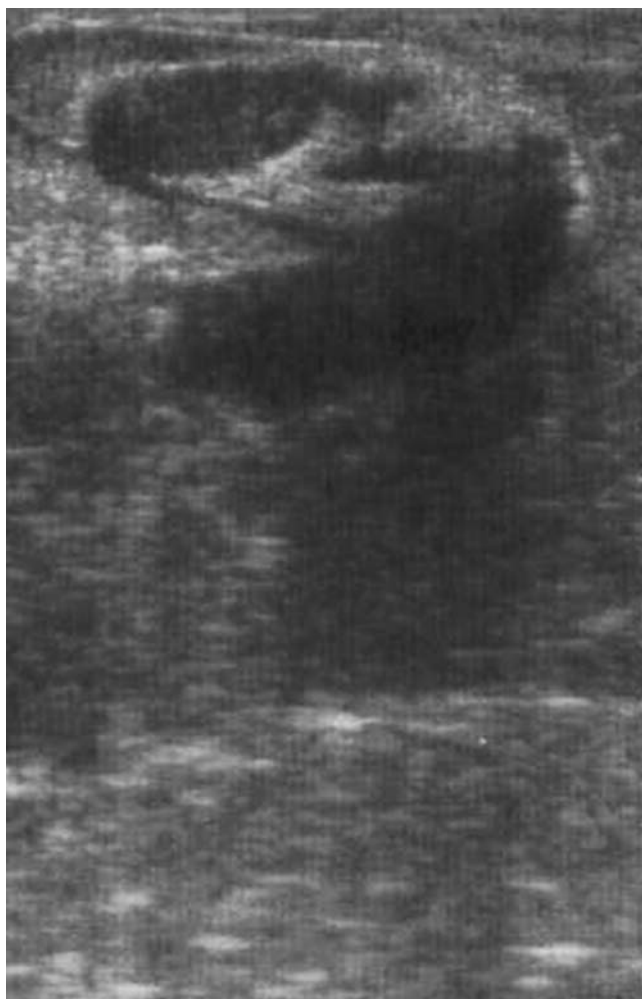Data was collected into a Microsoft Access database (Redmond, WA) and interpreted via chi-square testing and t-tests (SAS, Cary, NC and StatsDirect, version 2.3.7, Cheshire, UK) with significance set at a p-value of <0.05.

## RESULTS

A total of 126 patients were enrolled over 28 months. Patients had an average age of 42 (SD  $\pm$  15 years; range, 18–90), with Table 1 showing the prevalence of clinical and historical findings. Table 2 shows the body location of the cellulitis in our study population.

Treating physicians were asked pretest questions regarding 1) need for drainage procedure and 2) probability of subcutaneous fluid. Regarding the first pretest question, treating physicians believed that 44 (35%) patients needed some type of drainage procedure (aspiration or incision and drainage) before soft-tissue US. In response to the second question, the treating physicians' pretest probability for subcutaneous fluid in all subject patients averaged 35.5% (SD  $\pm$  24%), with a median of 30%.

Soft-tissue US performed by the emergency physicians found a fluid collection typical of abscess in 63 (50%) patients. Of these, 58 patients underwent a drainage



**Figure 2.** Ultrasound image of subcutaneous abscess showing irregular hypoechoic oval collection in subcutaneous tissue.

procedure, which included 12 percutaneous aspirations, 33 incision and drainage procedures, and 13 combination aspirations and incision–drainage procedures. Of these, 54 patients had fluid recovered, which included 46 with purulent collections (pus), 4 with serous collections, 2 with liquefied hematomas, and 2 with bloody serous collections. The five patients with sonographic fluid but no drainage procedure had very small collections (<1 cm diameter) and were discharged on antibiotics by treating

**Table 1**  
Clinical Features of Patient Population\* as Reported by the Patient

Clinical Feature	Number of Patients	Percentage
Male gender	67	53
Fever	25	20
Previous skin infection	63	50
Pain	38	30
Diabetes	27	21
HIV	8	6
Ethanol use	12	10

HIV = human immunodeficiency virus.  
\* N = 126.

**Table 2**  
Location of Soft-tissue Infection\*

Location	Number	Percentage
Leg	57	45
Trunk	29	23
Arm	15	12
Buttock	7	6
Foot	6	5
Neck	5	4
Face	4	3
Hand	3	2

\* N = 126.

physicians, with no return to the ED within 72 hours. Of the four patients who did not have fluid recovered from drainage procedures, two patients were discharged on antibiotics, and two patients had further consultation and imaging. There was no significant difference in the detection of a sonographic fluid collection between the groups of those who were believed not likely to need drainage and those who were believed likely to need drainage (46% vs. 57%,  $p = 0.26$ ).

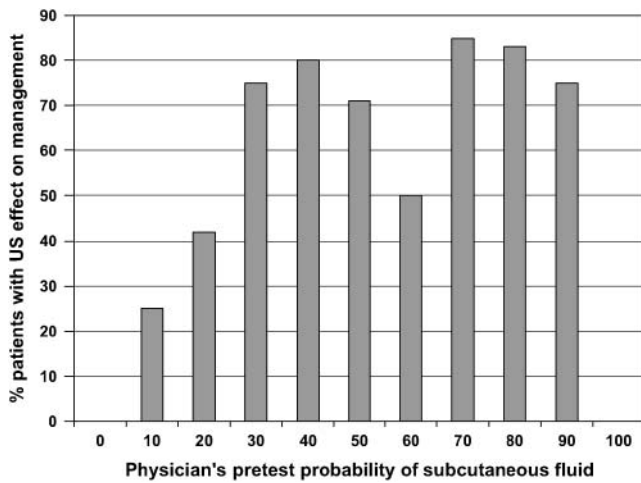
In those patients with no US fluid collection, four other diagnoses were made with soft-tissue US, including two patients with enlarged lymph nodes, one patient with a deep venous thrombosis, and one patient with superficial phlebitis.

Ultrasound changed the ED management of 71/126 (56%; 95% confidence interval [CI] = 47% to 64%) patients with cellulitis. Ultrasound was more likely to influence the management of the pretest group that was believed likely to need further intervention ( $p = 0.0066$ ).

In the pretest group believed not to need further drainage procedures ( $n = 82$ ), US changed the management plan in 39/82 (48%; 95% CI = 37% to 58%), with 33 receiving drainage and 6 receiving further diagnostics or consultation. All patients in this group receiving drainage were found to have abscesses. Further management changes included two magnetic resonance imaging tests, one computed tomography test, two venous US, and two surgical consultations.

In the pretest group in which further drainage was believed to be needed ( $n = 44$ ), US changed the management plan in 32/44 (73%; 95% CI = 58% to 85%), including 16 patients in whom drainage was no longer believed necessary and 16 patients who had further procedure guidance, diagnostic tests, or consultation. The 16 patients who had drainage procedures eliminated were treated with antibiotics and discharged from the ED without admission to the ED or hospital within 72 hours. The 16 patients with further interventions included 8 patients with alterations to their drainage procedure (placement, depth, incision, and location) and 8 patients who received further surgical consultation and imaging.

Ultrasound had a management effect in every decile of interval scores from 10% to 90% for treating physician’s pretest probability for subcutaneous fluid collection (Figure 3). When comparing the accuracy of physician pretest probability of subcutaneous fluid collection versus presence of a sonographic fluid collection (Table 3), there was a graduated increase in specificity and reduction in sensitivity as physicians’ pretest probability for



**Figure 3.** Treating physician’s pretest probability of subcutaneous fluid versus percentage of patients with a US effect on management.

subcutaneous fluid increased. However, the error rate (false positives + false negatives/total population) of physician pretest probability for subcutaneous fluid remained fairly high throughout all the intervals, ranging from 30% to 50%.

**DISCUSSION**

The care of the ED patient with soft-tissue infection can present significant clinical management issues. Although patients with obvious signs of abscess such as fluctuance and drainage declare themselves, those with cellulitic changes with induration and swelling may hide occult abscess formation. Invasive procedures may be used aggressively in these cases, but such an aggressive approach subjects both the patient and physician to the risk, pain, and time of an invasive procedure. Conversely, empiric treatment with only antibiotics can delay drainage procedures with the expense of repeat ED visits and possible worsening of the infection.

Ultrasound has been demonstrated to show fluid collections well, regardless of the site.<sup>9,10</sup> In the structure

of the skin, US can demonstrate not only normal subcutaneous structures but also the changes of cellulitis and abscess. Imaging with US also demonstrates the continuum of infection of cellulitis to abscess, because cobblestoning that is typical of cellulitis surrounding abscesses is often seen. For abscess, US provides assistance regarding the location of collections, especially in regard to skin and subcutaneous structures.<sup>6,11-13</sup>

We attempted prospectively to isolate the clinical scenario to the more uncertain cases in which US may assist the typical clinical approach. The results of the study suggest that patients with both low and high pretest need for drainage benefit from the use of US, but not for the same reason. For the low-pretest group, this change most often was the presentation of an occult fluid collection suggestive of abscess that prompted a drainage procedure. The high-pretest group had management changed in the opposite direction, with half having cessation of invasive procedures because of lack of sonographic abscess collection. Further imaging or consultation, although not as concrete a management change as procedural decision making, was changed especially in this high-pretest probability group. This pattern may have reflected more complexity to these particular cases that was not apparent on clinical examination.

Although there was a higher rate of management effect (73%) in the high-pretest group, it is hard to ignore the nearly 50% change in management for the low-pretest group. This clinical benefit of US for low-suspicion patients was supported by the results that showed an effect on management, even at pretest probabilities of 10% to 40%. One may consider that with pretest probabilities of <30%, the use of US would have minimal utility, but we would argue that an error rate of 30% is too high to preclude the use of US, a noninvasive, nonionizing bedside test.

Ultrasound most appropriately fits into the evaluation of soft-tissue infection in the ED in the post-physical examination phase. If there are clear signs of abscess, then appropriate drainage procedures are indicated without US. However if there is cellulitis, specifically with any question of occult abscess or need for drainage procedure, a soft-tissue US may be performed to determine the presence of subcutaneous fluid.<sup>6,12-14</sup>

Further study on the outcome of patients with soft-tissue US in undifferentiated skin infection may be useful, especially when US shows small fluid collections that may not be amenable to aspiration or incision. The role of soft-tissue US in populations such as immunocompromised populations, diabetics, intravenous drug users, and others with clinical risk factors for abscess would be helpful for further stratification of management. In addition, the study of patients with more aggressive soft-tissue infections in the ED with US is open to further investigation.<sup>15</sup>

**LIMITATIONS**

Although this study is suggestive of the efficacy of soft-tissue US in the management of patients with cellulitis in the ED, we acknowledge the following limitations. This study was a convenience sample of patients who were present or were referred to investigators who were

**Table 3**  
Accuracy Rate for Treating Physician’s Pretest Probabilities for Subcutaneous Fluid Collection Compared with Soft-tissue Sonographic Fluid Collection

Cutoff of Prior Probability	Sensitivity (%)	Specificity (%)	Total Error Rate (%)	Accuracy Rate
≥ 10	100	11.1	44.4	55.6
≥ 20	92.1	39.7	34.1	65.9
≥ 30	77.8	61.9	30.2	69.8
≥ 40	61.9	73.0	32.5	67.5
≥ 50	44.4	79.4	38.1	61.9
≥ 60	27.0	84.1	44.4	55.6
≥ 70	15.9	87.3	48.4	51.6
≥ 80	9.5	92.1	49.2	50.8
≥ 90	4.8	96.8	49.2	50.8

Total error rate = FP + FN/total population; accuracy rate = TP + TN/total population.

not blinded to the clinical findings. In addition, the investigator group had basic soft-tissue US skills. The small size of the investigator group, instead of inclusion of all emergency physician members of the department as sonologists, may have altered and possibly increased the effect on management. This study was performed on ED patients with cutaneous soft-tissue infection, and sonographic evaluation for abscess in different patient populations or deeper body regions may have a different outcome.

## CONCLUSIONS

Soft-tissue US changes physician management in approximately half of patients in the ED with clinical cellulitis. US may guide the management of cellulitis by detection of occult abscess and prevention of invasive procedures and may suggest further imaging or consultation.

## References

1. Meislen HW, Guisto JA. Soft-tissue infection. In: Marx JA, Hockberger R, Walls R, et al., eds. *Rosen's Emergency Medicine: Concepts and Clinical Practice*. 5th ed. St. Louis, MO: Mosby, 2002. pp 1949–53.
2. Butler KH. Incision and drainage. In: Roberts J, Hedges J, eds. *Clinical Procedures in Emergency Medicine*. 4th ed. Philadelphia, PA: Saunders, 2004. pp 717–26.
3. Chao H, Lin S, Huang Y, Lin T. Sonographic evaluation of cellulitis in children. *J Ultrasound Med*. 2000; 19:743–9.
4. Vincent L. Ultrasound of soft tissue abnormalities of the extremities. *Radiol Clin North Am*. 1988; 26: 131–44.
5. Bureau N, Chhem RK, Cardinal E. Musculoskeletal infections: US manifestations. *Radiographics*. 1999; 19:1585–92.
6. Squire BT, Fox JC, Anderson C. ABSCESS: applied bedside sonography for convenient evaluation of superficial soft tissue infections. *Acad Emerg Med*. 2005; 12:601–6.
7. Craig JG. Musculoskeletal ultrasound—infection: ultrasound-guided procedures. *Radiol Clin North Am*. 1999; 37:669–78.
8. Struk DW, Munk PL, Lee MJ, Ho SGF, Worsley DF. Imaging of musculoskeletal and spinal infection. *Radiol Clin North Am*. 2001; 39:277–303.
9. Swartz MN. Clinical practice. Cellulitis. *New Engl J Med*. 2004; 350:904–12.
10. Fly CA, Valley VT. Ultrasonographic evaluation of soft tissue infections in emergency department patients [abstract]. *Ann Emerg Med*. 2001; 38:S99.
11. Chandwani D, Shih R, Cochrane D. Bedside emergency ultrasonography in the evaluation of a perirectal abscess. *Am J Emerg Med*. 2004; 22:315.
12. Blaivas M. Ultrasound-guided breast abscess aspiration in a difficult case. *Acad Emerg Med*. 2001; 8: 398–401.
13. Page-Wills C, Simon BC, Christy D, Levitt MA. Utility of ultrasonography on emergency department of suspected cutaneous abscess [abstract]. *Acad Emerg Med*. 2000; 7:493.
14. Blaivas M, Lyon M, Brannam L, Duggal S. Intra-oral ultrasound in the diagnosis and real-time guided drainage of peritonsillar abscesses. *Acad Emerg Med*. 2005; 12:85–8.
15. Yen ZS, Wang HP, Ma HM, Chen SC, Chen WJ. Ultrasonographic screening of clinically-suspected necrotizing fasciitis. *Acad Emerg Med*. 2002; 9: 1448–51.

## Where to Find AEM Instructions for Authors

For complete instructions for authors, see the January or July issue of *Academic Emergency Medicine*; visit <http://ees.elsevier.com/acame/default.asp> and click on "Guide for Authors"; or contact SAEM via e-mail at [aem@saem.org](mailto:aem@saem.org), via phone at 517-485-5484, or via fax at 517-485-0801.