

RESPIRATION AND THE AIRWAY

Ultrasound-guided percutaneous tracheal puncture: a computer-tomographic controlled study in cadavers

M. Kleine-Brueggeney^{1,4†}, R. Greif^{1*†}, S. Ross³, U. Eichenberger¹, B. Moriggl⁵, A. Arnold² and C. Luyet¹

¹ University Department of Anaesthesiology and Pain Therapy, Inselspital, ² Department of ENT-Surgery, University Hospital of Bern and University of Bern, CH-3010 Bern, Switzerland

³ Institute of Forensic Medicine, Bern, Switzerland

⁴ Department of Anesthesiology, University of Washington, Seattle, WA, USA

⁵ Department of Anatomy, Histology, and Embryology, Innsbruck Medical University, Austria

* Corresponding author. E-mail: robert.greif@insel.ch

Editor's key points

- A cadaver study to evaluate the potential use of ultrasound for tracheal puncture.
- First-attempt success rate of 90% for tracheal puncture and 90% of these were midline.
- Relatively high incidence of thyroid tissue damage.
- Clinical evaluation of this technique is required.

Background. Ultrasound-guided techniques are increasingly used in anaesthetic practice to identify tissues beneath the skin and to increase the accuracy of placement of needles close to targeted structures. To examine ultrasound's usefulness for dilatational tracheostomy, we performed ultrasound-guided tracheal punctures in human cadavers followed by computer-tomographic (CT) control.

Methods. The trachea of nine cadavers was punctured using an in-plane approach with a longitudinal ultrasound visualization of the trachea. As soon as a loss of resistance was felt, or air/fluid could be aspirated into the attached syringe, the syringe was disconnected and the ultrasound transducer set aside. Thereafter, a cricothyroidotomy guidewire was inserted through the needle into the trachea. The needle was then removed, leaving the wire in place and a control CT imaging of the neck and the chest was performed. Primary outcome was successful wire insertion into the trachea.

Results. Tracheal puncture and wire insertion was successful in eight of nine cadavers at the first attempt and in one at the second attempt (total of 10 puncture attempts, nine successful). In eight of nine successfully inserted wires, the wire was placed on the defined midline.

Conclusions. Ultrasound guidance can facilitate successful tracheal puncture. However, combining an in-plane approach with a longitudinal ultrasound visualization of the trachea neither guarantees an exact midline puncture nor allows detection of a misplaced guidewire.

Keywords: anatomy, airway; complications, asphyxia; equipment, airway; equipment, ultrasound machines; intubation, tracheostomy

Accepted for publication: 10 January 2011

Airway management is a core competence of anaesthetists and critical care physicians. In a cannot ventilate, cannot intubate emergency, and in critically ill patients requiring tracheostomy in an intensive care unit, percutaneous or surgical airway access is recommended by current guidelines.^{1,2} This involves the successful localization of the trachea and the successful placement of a needle to guide a wire, or of the scalpel.

The classic approaches used are either a cricothyroidotomy or a percutaneous tracheostomy. The cricothyroidotomy's advantage is its relatively easy access due to the superficial position of the larynx, but it includes the danger of cricoid cartilage necrosis.^{3–6} Compared with the larynx, the trachea lies deeper and a visual aid to guide the puncturing needle might be helpful. Because ultrasound equipment is widely used and

many clinicians feel comfortable with real-time ultrasound needle guidance for vascular access or for regional anaesthesia, an ultrasound approach to guide invasive airway procedures might be an important option.

To examine the potential use of ultrasound for airway access to the trachea, we attempted puncture of the trachea of human cadavers with ultrasound-guidance and inserted a wire. We assessed the tracheal wire position with computer-tomographic (CT) imaging.

Methods

This prospective open observational study was performed on nine cadavers in legal custody of the Department of

[†]These authors contributed equally to this work.

Anatomy, Histology and Embryology of the Medical University, Innsbruck, Austria, with institutional approval. A special embalming fluid composed of ethanol, glycerol, and phenol (close to the method described by Thiel)⁷ was used to keep the cadaveric tissue in a condition suitable for sonographic studies, as demonstrated previously.⁸⁻¹²

Two investigators each performed five ultrasound-guided tracheal punctures and wire insertions. A portable SonoSite[®] MicroMax (SonoSite Inc., Bothell, WA, USA) with the C11e, 8-5 MHz, 11 mm broadband curved array transducer (SonoSite Inc.) was used. This transducer is available in the operating theatres and emergency room in our hospital. With the small curved array transducer, we aimed to display a broad section of the trachea and the small skin contact surface avoided difficulties with needle insertion. At least, three tracheal rings could be visualized without impeding the needling during the puncture of the trachea.

The cadavers were placed supine with the head in a neutral position. The curved ultrasound transducer was

then positioned on the midline over the lower anterior neck to visualize the skin and underlying tissues, including the laryngeal and tracheal cartilages (Fig. 1). Subsequently, the trachea was scanned in a transverse axis to define the midline (Fig. 2). Thereafter the axis of the transducer was tilted to achieve a longitudinal scan of the trachea. The aim was to perform the puncture between the 1st and 2nd, or 2nd and 3rd tracheal cartilage on the midline of the trachea with an in-plane needle approach (Fig. 1). The puncture was performed caudally with an 18 G thin wall needle. As soon as a loss of resistance was felt, or air or fluid could be aspirated into the attached syringe, the ultrasound probe was set aside and the syringe was disconnected. A 0.035 in guidewire from a pre-assembled cricothyrotomy kit (Melker Emergency Cricothyrotomy Catheter Set C-TCCS-400, Cook Critical Care Inc., Bjaeverskov, Denmark) was inserted through the needle into the trachea as a guidance for further tracheostomy. The needle was then removed over the wire, leaving the wire

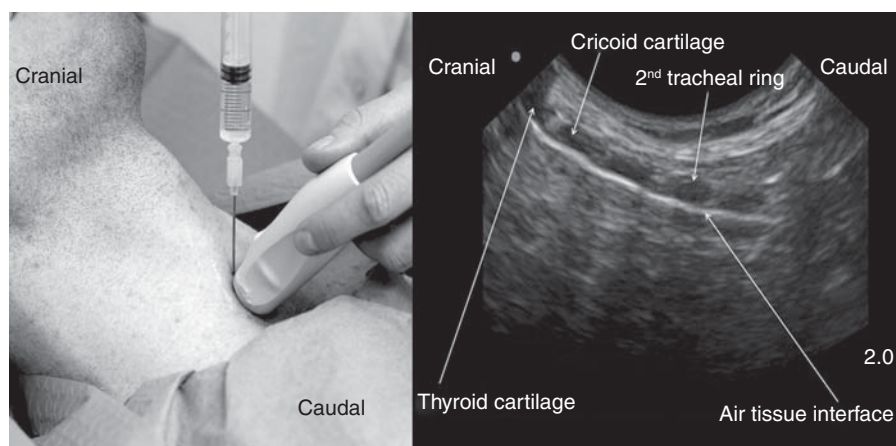


Fig 1 Photo of the position of the probe and needle (photo taken on a model instead of a cadaver, published with consent), and corresponding ultrasound scan in a longitudinal axis with the probe placed in the suprasternal notch. This figure shows how the trachea lies deeper the more distally the puncture is performed. The echogenic line is consistent with an air-tissue interface at the anterior wall of the trachea. The cartilages are echolucent; the posterior wall of the trachea is not visible.

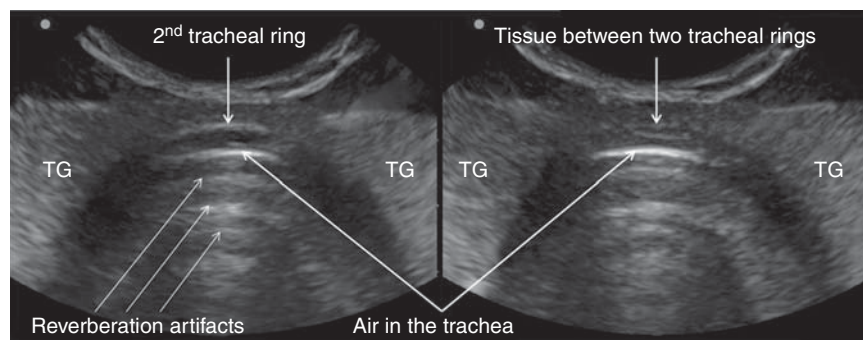


Fig 2 Ultrasound scan in a transversal axis with the probe placed in the jugular depression. TG, thyroidal gland.

Table 1 Anatomical findings and complications of the nine successful ultrasound-guided wire insertions

	Mean (sd) or n (%)
Shortest possible access to the trachea in the transverse plane (mm)	8.6 (2.8)
Cervical puncture level (tracheal ring 1/between tracheal ring 1–2/2–3/3–4)	1 (11)/4 (44)/2 (22)/2 (22)
Lesion of tracheal structures (yes/no)	1 (11)/8 (89)
Lesion of thyroid structures (no lesion/isthmus/lobe)	1 (11)/7 (78)/1 (11)

in place. A control CT scan of the neck and the upper part of the thorax was undertaken (Synergy; GE Medical Systems, Milwaukee, WI, USA).

Primary outcome was successful wire insertion into the trachea. Secondary outcome was correct midline wire localization using the described inline puncture technique. The exact site of tracheal puncture, evaluated by the control CT scan, was described by a clockface, with 12 o'clock being the anterior tracheal wall on the midline. Starting from this, the tracheal midline range was defined as all puncture sites between 11 and 1 o'clock.

Secondary outcome variables also included: depth of the trachea, defined as the distance from the skin to the anterior tracheal wall of the transverse plane in millimetres; the level of the puncture site defined by the cricoid cartilage, thyroid cartilage, and tracheal rings; signs of perforation of the tracheal ring, cricoid, or thyroid cartilage; and damage to thyroid tissue.

All control CT scan outcomes were evaluated by a forensic radiologist who was not otherwise involved in the study. General information about the cadavers such as age at death, height, weight, and BMI was provided by the Department of Anatomy, Histology, and Embryology, Innsbruck Medical University, Austria.

Results

A total of 10 ultrasound-guided percutaneous tracheal punctures and wire insertions in nine cadavers (seven males and two females) were performed. The cadavers' mean age (range) at death was 72 (50–91) yr, mean body weight (sd) was 69 (6) kg, mean height was 173 (6) cm, and mean BMI was 24 (6) kg m⁻². None had a history of traumatic head or neck injury.

Wire insertion into the trachea was successful in eight of nine cadavers (89%) at the first attempt and in one at the second attempt.

Ultrasound visualization of the tracheal rings was possible in all cases (Figs 1 and 2). The trachea was punctured at sites varying from 10 to 1 o'clock (in the transverse plane). Eight of nine (89%) successful wires were placed at the defined tracheal midline range between 11 and 1 o'clock (Table 1). Damage to the thyroid tissue was found in eight out of nine successful punctures (89%). Seven of these were located at the thyroid isthmus, which is difficult to visualize with ultrasound, but one guidewire perforated a thyroid lobe, which was in the normal anatomical position. In this

case, the trachea was not penetrated in the midline, but at 10 o'clock. One CT scan showed that the wire had perforated a tracheal ring.

A failure of tracheal puncture and wire insertion at the first attempt occurred in one cadaver with a BMI of 24 kg m⁻². The distance between the skin and trachea in the midline of the transverse plane was 12 mm. The wire penetrated the right lobe of the thyroid, and touched and passed, but did not penetrate the trachea. The second attempt was successful and uneventful.

Discussion

Ultrasound is a well-established technology in anaesthesia for regional nerve blocks and for vascular access. However, only one study group has reported the use of ultrasound-guided percutaneous dilatational tracheostomy.^{13 14} In contrast to their 100% first-attempt success rate, we had an 89% first-attempt success rate in the cadavers studied. In one cadaver, the CT scan revealed that the wire was not placed in the trachea despite an uneventful and accurate real-time ultrasound-guided puncture of the trachea with aspiration of air as confirmation for the correct needle-tip position. Possible explanations include movement of the needle tip when the pressure of the ultrasound probe was removed before insertion of the wire or during removal of the attached syringe and insertion of the wire. Although the operators were experienced in airway management and in the use of ultrasound, the extra-tracheal puncture was not detected by ultrasound, but by the CT scan. Displacement of the needle and the wire out of the trachea has been reported recently.¹⁵

During the study, an effort was made to avoid a puncture of the cricothyroid ligament. The aim was to puncture the airway below the first tracheal ring as cricothyroidotomy bears the risk of necrosis of the cricoid cartilage. Current clinical practice at our university hospital is to convert a cricothyroidotomy into a tracheostomy. Tracheostomy performed at the correct site does not need further surgical intervention. An obvious disadvantage of this rather caudal puncture is the fact that the trachea lies deeper beneath the skin. Without the help of ultrasound imaging, many clinicians would therefore prefer cricothyroidotomy for emergency airway access.

Midline placement of the needle and the guidewire minimizes trauma if placed exactly between two tracheal rings. If the guidewire deviates too much from the midline, tissue

damage is much more pronounced during the subsequent dilatation. Our results show that the ultrasound-guided technique, with a good ultrasound image and experience in using ultrasound, allowed midline placement of the wire in 89%. Placement of the transducer transverse to the tracheal cartilage and use of short-axis ultrasound imaging allows continuous visualization of the tracheal midline. However, it is difficult to identify the right space between the tracheal rings and to differentiate cartilage from air. Therefore, we kept the transducer in a longitudinal plane and advanced the needle 'in plane' to the transducer. This should allow the needle to be followed as it is advanced, if it is kept inline throughout, while the laryngeal cartilage and the tracheal cartilages are visible and differentiable from the air between the cartilages.

The CT images revealed a high incidence of thyroid tissue damage. Perforation of the thyroid, especially the isthmus, is difficult to avoid during dilatational tracheostomy but rarely causes problems.¹⁶ However, rare but fatal complications like lethal arterial bleeding from a thyroid artery^{17 18} or from an avulsed subclavian artery¹⁹ have been reported during or after tracheostomy. Even by using ultrasound visualization and guidance, we could not avoid thyroid damage, and we still recommend avoiding tracheal access below the third tracheal ring.¹⁷ We found a tracheal ring perforation in one cadaver (11%). This, however, is lower than the 36% previously reported¹³ which could be due to improved ultrasound quality since 2000.

This study is limited by the fact that it was performed on cadavers. Accidental vascular puncture could not be detected as the cadavers have a low intravascular volume, especially in the venous system. Nevertheless, it would not have been possible to perform this study in patients. A CT scan control would not have been possible to perform due to ethical considerations because of the exposure to radiation and the availability of a CT scan at the given moment of the surgical access to the trachea in a patient with a critical airway.

The frequent damage to the thyroid in our study might be a limitation of the percutaneous approach to the trachea, due to the risk of bleeding. Interestingly, the use of ultrasound did not avoid thyroid damage. The clinical importance of this needs to be followed up, although serious bleeding after percutaneous tracheostomy is rare.

We did not measure time for performance in this feasibility study and it was not an issue. We did not perform any sample size calculation because of the observational character without a control group. Performing the same procedure in more cadavers would need considerable resources and generate more costs. A larger study of ultrasound for airway access should be undertaken in patients.

In conclusion, ultrasound guidance can facilitate successful tracheal puncture and wire insertion. However, combining an in-plane approach with longitudinal ultrasound visualization of the trachea does not guarantee midline puncture, or detection of a misplaced guidewire. Ultrasound visualization does not avoid damage to thyroid tissue, especially when a more caudal approach is chosen.

Acknowledgement

We thank the staff of the Department of Anatomy, Histology, and Embryology of the Medical University of Innsbruck for providing us the cadavers and the location for the study.

Conflict of interest

None declared.

Funding

This research project was paid for with departmental research grants only. The ultrasound machine was generously provided by SonoSite Austria, Sittendorf, Austria.

References

- 1 Practice guidelines for management of the difficult airway: an updated report by the American Society of Anesthesiologists Task Force on Management of the Difficult Airway. *Anesthesiology* 2003; **98**: 1269–77
- 2 Henderson JJ, Popat MT, Latto IP, Pearce AC. Difficult Airway Society guidelines for management of the unanticipated difficult intubation. *Anaesthesia* 2004; **59**: 675–94
- 3 Quiney RE, Gould SJ. Subglottic stenosis: a clinicopathological study. *Clin Otolaryngol Allied Sci* 1985; **10**: 315–27
- 4 Dollner R, Verch M, Schweiger P, Deluigi C, Graf B, Wallner F. Laryngotracheoscopic findings in long-term follow-up after Griggs tracheostomy. *Chest* 2002; **122**: 206–12
- 5 Hotchkiss KS, McCaffrey JC. Laryngotracheal injury after percutaneous dilatational tracheostomy in cadaver specimens. *Laryngoscope* 2003; **113**: 16–20
- 6 Raghuraman G, Rajan S, Marzouk JK, Mullhi D, Smith FG. Is tracheal stenosis caused by percutaneous tracheostomy different from that by surgical tracheostomy? *Chest* 2005; **127**: 879–85
- 7 Thiel W. The preservation of the whole corpse with natural color. *Ann Anat* 1992; **174**: 185–95
- 8 Greher M, Kirchmair L, Enna B, et al. Ultrasound-guided lumbar facet nerve block: accuracy of a new technique confirmed by computed tomography. *Anesthesiology* 2004; **101**: 1195–200
- 9 Eichenberger U, Greher M, Kirchmair L, Curatolo M, Moriggl B. Ultrasound-guided blocks of the ilioinguinal and iliohypogastric nerve: accuracy of a selective new technique confirmed by anatomical dissection. *Br J Anaesth* 2006; **97**: 238–43
- 10 Kirchmair L, Entner T, Kapral S, Mitterschiffthaler G. Ultrasound guidance for the psoas compartment block: an imaging study. *Anesth Analg* 2002; **94**: 706–10, table of contents
- 11 Luyet C, Eichenberger U, Greif R, Vogt A, Szucs Farkas Z, Moriggl B. Ultrasound-guided paravertebral puncture and placement of catheters in human cadavers: an imaging study. *Br J Anaesth* 2009; **102**: 534–9
- 12 Luyet C, Eichenberger U, Moriggl B, Remonda L, Greif R. Real-time visualization of ultrasound-guided retrobulbar blockade: an imaging study. *Br J Anaesth* 2008; **101**: 855–9
- 13 Sustic A, Kovac D, Zgaljardic Z, Zupan Z, Krstulovic B. Ultrasound-guided percutaneous dilatational tracheostomy: a safe method to avoid cranial misplacement of the tracheostomy tube. *Intensive Care Med* 2000; **26**: 1379–81
- 14 Sustic A, Krstulovic B, Eskinja N, Zelic M, Ledic D, Turina D. Surgical tracheostomy versus percutaneous dilatational tracheostomy in patients with anterior cervical spine fixation: preliminary report. *Spine (Phila Pa 1976)* 2002; **27**: 1942–5, discussion 5

- 15 Dunne K, Ball D, Jefferson P. Cannula cricothyroidotomy: management of false-negative aspiration. *Anaesthesia* 2009; **64**: 1375
- 16 Sustic A. Role of ultrasound in the airway management of critically ill patients. *Crit Care Med* 2007; **35**: S173–7
- 17 Praveen CV, Martin A. A rare case of fatal haemorrhage after tracheostomy. *Ann R Coll Surg Engl* 2007; **89**: W6–8
- 18 Della Puppa A, Pittoni G. Inferior thyroid artery bleeding: a life-threatening complication of non-surgical tracheostomy. *Minerva Anesthesiol* 2001; **67**: 483–5.
- 19 Shlugman D, Satya-Krishna R, Loh L. Acute fatal haemorrhage during percutaneous dilatational tracheostomy. *Br J Anaesth* 2003; **90**: 517–20